

Original Article

A Study on Management of Mucormycosis - Comparative Study Between Multiple Staged Surgical Procedures and Single Surgical Procedure in a Tertiary Care Centre

Sankaranarayanan G*, Chandramouli MP**, Raghavi VP***

*Professor, **Assistant Professor, ***PostGraduate, Department of ENT, Madras Medical College, Chennai, India.



Dr. G. Sankaranarayanan did his basic graduation from Stanley Medical College, Post Graduation Diploma from Stanley medical college and Masters from Madras Medical College, Chennai. Has done DNB and is a member of National Academy of Medical sciences. Has held teaching posts in Kilpauk Medical College (Chennai), KAPV Medical College (Trichy) and currently is a Professor of ENT and Senior ENT Surgeon at Madras Medical College and Rajiv Gandhi Govt General Hospital, Chennai.

Corresponding author - Dr Chandramouli MP (drchandramoulient@gmail.com)

Chettinad Health City Medical Journal 2017; 6(4): 158 - 164

Abstract

Background Mucormycosis is an invasive fungal infection most commonly affecting immuno-compromised individuals. It is a rapidly progressive, life threatening infection.

Objective To study the various treatment modalities and their outcome

Method In this study we retrospectively and prospectively investigate 37 patients of rhino-maxillary/ rhino-orbital/ rhino-cerebral mucormycosis between January 2016 and September 2017. We analysed the risk factors, clinical features, histopathological reports, radiological investigation and treatment (medical and surgical – Multiple staged surgical procedures and Single stage procedure) along with the outcome. We compared multiple staged surgeries with single debridement and followed up the patient till October 2017.

Results Diabetes was the single most important risk factor (31 patients) – of which the recent status of glycemic control was the most contributing factor. Other risk factors included – electrolyte imbalance, anaemia and deranged renal parameters. Out of 23 patients treated with multiple staged surgeries, 29 were free of disease, 2 lost to follow up and 1 died. Out of 11 patients treated with single surgical procedure, 5 were cured, 3 lost to follow up and 3 were dead (2 due to other reasons). The 3 patients who weren't operated died within 2 weeks.

Conclusion Multiple staged surgical procedures proved to have a much better prognosis compared to a single staged procedure.

Keywords Rhino-maxillary, Rhino - orbital, Rhino - cerebral, Mucormycosis, Multiple staged procedures, Diabetes Mellitus, Outcome.

Introduction

Mucormycosis is a rare and potentially fatal opportunistic fungal infection first described by Paltauf in 1885 in human beings.¹ It is the third most common opportunistic fungal infection after *Candida* and *Aspergillus*. It is caused by saprophytic fungi (Zygomycetes, Class – Mucorales, Order - Mucoraceae family, Species - *Rhizopus*, *Rhizomucor*, *Mucor*, *Absidia*). It has a worldwide distribution and an annual incidence of 0.4-1.7 cases/10,00,000 population.² The spores are ubiquitous in nature (present in soil, decaying organic matter) and inhalation is the mode of spread to the nose and paranasal sinuses. In patients who are immunologically or metabolically compromised, it progresses rapidly through angioinvasion and caustic tissue necrosis. Most common type of mucormycosis that affects the body is Rhino-cerebral mucormycosis.³ It has a poor prognosis and has higher mortality rate - 50%.⁴ As mentioned in the literature, early diagnosis and prompt aggressive management is the key for successful outcome.⁵

Materials

Aims And Objectives: To study the various treatment modalities for rhino-orbital Mucormycosis and their outcome

Study Place: Institute of Otorhinolaryngology, Madras Medical College and Rajiv Gandhi Government General Hospital, Chennai - 600003.

Study Design: Longitudinal Study

Study Duration: January 2016 to September 2017

Ethical Clearance: Approved by Ethics Committee; Rajiv Gandhi Government General Hospital

Inclusion Criteria: All patients presented to the ENT department with Sino-orbital-cerebral symptoms (confirmed histologically as mucormycosis)

Exclusion Criteria: No specific clinical exclusive criteria, except the patients who were not willing to take part in the study.

Methodology

Informed consent was obtained. A detailed history was taken and a thorough clinical evaluation was done. All the patients underwent routine blood investigations along with Computed Tomography imaging. In cases with suspicion of complication, Magnetic Resonance Imaging was also done. For any abnormalities in the above said investigations, relevant expert opinion from other speciality departments like Diabetology, Nephrology, Ophthalmology, and Neurology were obtained.

From the data; the risk factors, clinical presentation and investigations were analysed.

Categories

Patients were classified into 3 categories:

- Category 1 – Sino-nasal/Rhino-maxillary – infection of nasal mucosa and paranasal sinuses
- Category 2 – Rhino-orbital – Orbital involvements leading to orbital fissure syndrome and orbital apex syndrome
- Category 3 – Rhino-cerebral – Cerebral involvement leading to cavernous sinus thrombosis, occipital and frontal lobe infarctions

Patients in all the categories of mucormycosis were managed with Medical and/or Surgical treatment.

Medical Treatment

Medical treatment included empirical antibiotics, antifungals and supportive treatment for stabilizing the metabolic derangement. The main antifungal administered was Inj. Amphotericin B Emulsion with a daily dose of 1mg/kg body weight in 500ml of 5% Dextrose (cumulative dosage: 1.5- 2g, given over a period of 25-45 days). SypPosaconazole (200mg TDS) was administered for patients with reaction to Inj. Amphotericin and 3 patients needed prolonged treatment after completion of Inj. Amphotericin course. At the time of discharge, oral Itraconazole (200mg BID) was advised for patients with the suspicion for residual/recurrence of the disease.

Surgical Treatment

Surgical treatment was based on the extent of involvement of mucormycosis and presenting complications. It included various procedures including endoscopic radical nasal debridement and extended wherever necessary with medial maxillectomy, endoscopic orbital decompression, sinus tract excision and total maxillectomy. The procedures were done under local or general anaesthesia. Endoscopic orbital decompression was done incising the orbital periosteum and removing the necrosed, devitalised tissue. Total Maxillectomy was done under general anaesthesia via a sublabial approach and the defect was closed using obturator.

Most of the patients had metabolic derangements at the time of presentation, (with respect to their pH/diabetic/renal/electrolyte/anaemic parameters) due to which an immediate aggressive extensive

debridement under general anaesthesia was not likely possible. Histopathological confirmation also delayed the definitive procedure.

In our study, based on the therapy employed, there were 3 surgical groups. Patients with typical presentation who were willing to undergo multiple surgeries under LA and GA were grouped under GROUP - A. Patients with atypical presentations who were not willing for surgery under LA were under GROUP - B. Patients who refused any kind of surgical therapy were grouped as GROUP - C.

Group - A:

Multiple Staged Surgical Procedures:

These patients underwent initial radical endoscopic debridement under LA during which biopsies were also taken. Later, after stabilization of their metabolic status, they underwent a more definitive procedure like Extensive Debridement with medial maxillectomy (where ever necessary)/ Endoscopic Orbital Decompression/ Total Maxillectomy. Following this, they were also taken up for nasal endoscopy under LA at regular intervals (till they were discharged from the hospital) and debridements were done as and when needed.

Group - B: Single Surgical Procedure:

These patients were initially metabolically stabilized. Histopathological confirmation as Mucormycosis was obtained. General anaesthesia fitness was obtained and then the patients were directly taken up for extensive debridement procedures.

Group - C:

This group includes the patients who did not undergo any surgical therapy. Informed written consent was obtained for patients undergoing surgery.

Follow Up

All the patients were followed up with nasal endoscopy and occasional radiological investigation. They were followed up for a period of 3 months to 22 months (mean duration of 12 months). Comparison of the outcome was made between 3 groups.

Results and Analysis

Age Distribution

Peak incidence was between 40- 49 years, 12 patients (i.e. 32%). 95% were between the age group of 30-69 years. 8 were between 30-39 years, 9 were between 50-59 years and 6 were between 60-69 years. There were no cases reported below the age of 30 years. Only 5% (i.e. 2 patients) of the patients presented were above the age of 70. (Fig 1)

Sex Distribution

There were 19 (51.4%) male and 18 (48.6%) female patients.

Seasonal Variation

31 patients presented between the months of September and March.

Factors Associated with the Disease

In our study, Diabetes Mellitus was the single most important and most common risk factor associated for the development of Mucormycosis (31/37). Out of this, 23 patients had uncontrolled Diabetes Mellitus and 11 patients had diabetic ketoacidosis. Other factors which were associated with mucormycosis were deranged renal parameters (20 patients) and anaemia (16 patients). History of steroid therapy was present in 2 patients (SLE and Interstitial nephritis). 1 patient had

HIV and 2 patients had HbsAg

History of recent admissions was present in 20 patients, of which 14 were unrelated to Rhino-cerebralmucormycosis. History of recent trauma was present in 6 patients.

Using Pearson Chi-Square Test for association of Diabetes Mellitus with Mucormycosis, p value of <0.05 was obtained, demonstrating a statistically significant positive association between the two.

Test for association between Deranged Renal Parameters and Clinical features showed p value of 0.031. Since it is <0.05, a positive statistically significant association between the two is present.

Using the same, test for association between anaemia and stage of disease was assessed and p value of 0.052 (>0.05) was obtained, which implies that it is statistically insignificant. This may be due to the small sample size.

Statistically no positive association was found between mucormycosis and factors like hypertension, smoking or alcoholism.

Onset of Disease

Among the study population, 4 patients (11%) presented with a fulminant course – symptoms developed within a week. 24 patients (65%) presented acutely within 1 week to 1 month and 9 patients (24%) had a more chronic course.

Clinical Features

The most common symptom was nasal complaints (86%). Other symptoms were headache (75%), trigeminal nerve involvement (70%) presenting with hypoesthesia over the cheek, ocular symptoms—orbital cellulitis (65%) and visual disturbance (51%), total loss of vision (35%), facial nerve palsy (32%), palatal involvement (24%) and fever (24%). Only 1 patient presented with osteomyelitis of the maxilla.

Out of the 37 patients, examination of nasal cavity showed the presence of eschars in 23 patients and only unhealthy mucosa in 14 patients.

Categories

Based on their Category of presentation, they were classified into 3 groups

Category I – Sino-nasal/Rhino-maxillary – 11 patients – 29.7%

Category II – Rhino-orbital – 17 patients – 46% (most common)

Category III – Rhino-cerebral – 9 patients – 24.3%

Histopathological Examination

Histopathological examination revealed that 24 patients had features exclusively of Mucormycosis and 13 patients had mixed fungal infection with predominance of Mucormycosis. Grocott-Gomorrithanamine silver staining was done in 11 cases to confirm the diagnosis.

Pearson Chi-Square test was done for evaluating the association between histopathology reports and the aggression of the disease process. p value obtained was > 0.05 – which is statistically insignificant.

Radiological Findings

In the CT scan, almost all patients had features of either mucosal thickening or homogenous opacity. Involvement of the maxillary sinus was present in majority of the patients, with involvement of ethmoidal in a subset. Sphenoid and frontal sinuses were involved only in 3 patients. 7 patients had bony erosion. 19 patients had Retromaxillary involvement (including lesions in pterygopalatine area and infratemporal fossa). 16 patients had Orbital apex involvement. 10 patients had features suggestive of Cavernous sinus involvement and 5 patients had brain infarct. Some patients underwent MRI - brain and paranasal sinuses, to identify orbital apex syndrome, cavernous sinus thrombosis and brain infarcts.

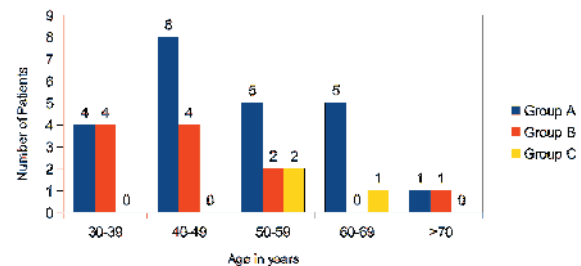


Fig 1 : Age distribution

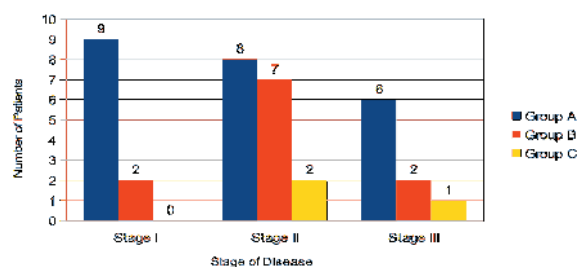


Fig 2 : Categorization of the three groups

Treatment

Patient Characteristics in different Groups are shown (Fig 2)

Group – A has 23 patients out of which, 9 patients in category I, 8 in category II and 6 in category III

Within 3 days of admission, all the patients underwent initial aggressive endoscopic debridement under LA, where a biopsy was also taken. This was followed by multiple staged surgical procedures under LA or GA.

Meanwhile, the metabolic status of the patients was stabilized and disease was confirmed with biopsy.

Within 10 days, out of these 23 patients, 18 were taken up for another debridement (7 under GA and 11 under LA). 4 patients underwent orbital decompression (2 under GA and 2 LA) and 1 patient underwent both orbital decompression and maxillectomy under GA. In the following week, out of 23 patients, 5 patients were taken up for endoscopic debridement in which 3 patients also underwent orbital decompression (3 under GA and 5 under LA). 3 patients were taken up for sublabialmaxillectomy under GA. In 11 patients, nasal endoscopy was done and nasal mucosa was found to be healthy. 1 patient deteriorated.

By the end of 3rd week 1 patient deteriorated (altered GCS) in spite of 3 surgical debridements and Inj. Amphotericin. MRI showed Cavernous sinus thrombosis and frontal lobe infarct. Patient died in few days.

By 4th week, out of 22 patients, 10 patients were taken up for relook nasal endoscopy where 4 patients needed minimal debridement and 1 patient underwent total maxillectomy under GA.

Before discharge, nasal endoscopy was done for all the patients to make sure there was no residual disease.

All the patients received a full course of Inj. Amphotericin B (1.5-2g) except 1 patient. Dosage of Inj. Amphotericin was decided based on their renal status after Nephrologist opinion. One patient developed allergic reaction to Inj. Amphotericin B and hence was changed over to Syp. Posaconazole 200 mg TDS.

Of these 23 patients, till date, 20 are living free of disease. 2 were lost to follow up, though both had been followed upto 4 months and were free of disease. 1 patient died.

In Group B there were 11 patients; 2 in category I, 7 in category II and 2 in category III.

3 patients had atypical clinical features with no eschars and hence were included in this group. 8 other patients were not willing for surgery under LA.

For these patients, metabolic derangements were first addressed while awaiting histopathology report. They were taken up for surgery around 2 weeks after their admission. In the meantime, they received Inj. Amphotericin.

9 patients underwent definitive surgery under GA around 15 days after presentation. 1 patient had already undergone orbital exentration elsewhere and was not willing for another surgery. 1 patient worsened in the meantime and was taken up for debridement on the 7th day. But the patient worsened and died in a week. 5 patients were living free of disease. 3 patients have been lost to follow-up at present. But all of them were followed upto 3 months post-surgery and were free of disease till then. Of the 3 patients who died, 2 were due to the disease (1 during treatment and the other 6 months post treatment). The third patient died due to other cause (SLE with pulmonary complication).

In Group C there were 3 patients. 2 of them were in category II and 1 patient was in category III.

None of them underwent any surgical procedures. All three had defaulted Amphotericin therapy. One patient deteriorated rapidly even before a definitive procedure could be done. The second patient refused surgical treatment and had defaulted Inj. Amphotericin (1g). The third patient refused any kind of treatment after 200mg of Inj. Amphotericin.

All three of them died. 1 patient rapidly deteriorated and died in the hospital within 5 days. The other 2 patients died within 2 weeks. (Table 1)

GROUPS	Group - A	Group - B	Group - C
Total no of patients	23	11	3
Free of disease	20(95%)	5(63%)	0(0%)
Lost to Follow up	2	3	0
Died	1	3	3

Table 1 : Follow up of patients

Pearson Chi square test was applied to evaluate the association between multiple staged surgeries and the outcome. A p value of 0.002 (< 0.05) was obtained, which is statistically significant, proving that there is a positive association. Also, on comparing the outcome between Multiple Staged Procedures and Single Staged Procedure, Multiple staged Procedures had significantly better outcome. Statistically, there was also a significant positive association between administration of Inj. Amphotericin and the outcome i.e. p value < 0.05

Follow Up

Of the 24 patients who were followed up for more than 6 months, the most common complaint was persistent headache – unilateral frontal region (19 patients), despite being disease free clinically and radiologically. None of the neurological deficits involving the cranial nerves had improved: vision (Optic nerve), extraocular movements (Oculomotor, Trochlear, Abducent Nerves), facial nerve palsy or other cranial nerve involvement – none recovered in spite of the patients being disease free.

Case Report – Elaboration of a typical case and the management

A 53 year old female, known case of type 2 diabetes mellitus for the past 10 years, who was on regular treatment, came with history of high grade intermittent fever for the past 15 days, with swelling, decreased sensation and headache on the right side of the face for the past 10 days and not associated with nausea or vomiting or visual disturbances. She also presented with nasal obstruction on the right side with continuous nasal discharge which was purulent and foul smelling. She was also presented with the history of deviation of angle of mouth to right side, incomplete closure of right eye and ulcers in the palatal region for the past 7 days.

She was initially treated with antibiotics and antipyretics for fever. History of recent change to Inj.H.Insulin due to poor glycemetic control was present.

On examination, a diffuse swelling was present over the right maxillary region associated with loss of sensation in the right infraorbital region. Anterior rhinoscopy of right nasal cavity showed necrotic lesion and eschar over the lateral wall and floor (Fig 3a). Mucopurulent foul-smelling discharge was present. Left nasal cavity was normal. Slough covered ulcer of size 3x2cms was present in the right half of the bony palate with loss of sensation over the area along with loosening of teeth in the upper right jaw (Fig 3b). Grade - 3 Lower motor neuron Facial nerve palsy was also present.

CT Paranasal Sinus revealed soft tissue density lesion involving the right cheek, right maxillary antrum, right ethmoid and frontal sinus extending into right orbit with thickening of inferior rectus. Erosion of inferior orbital wall and posterolateral wall of right maxilla and right side of hard palate was noted. (Fig 3c)

Provisional Diagnosis was made as Right Sino-nasal Mucormycosis with Right lower motor neuron Facial Palsy. Patient was started on Intravenous Antibiotics, Inj. Amphotericin, Inj.H.Insulin and other supportive medications. On the second day, Endoscopic debridement was done under LA. A week later, under LA, patient was again taken up for endoscopic debridement. The palatal lesion was increasing inspite of the debridement and Inj. Amphotericin.

Repeat CT scan showed features suggestive of intra-orbital extension with erosion of right hard palate, walls of right maxillary antrum and right orbital floor with residual soft tissue in right maxilla. Ethmoidal, frontal and sphenoidal sinusitis was also noted. (Fig 3d)

After obtaining diabetic control and fitness for surgery, right total maxillectomy was done under general anaesthesia (Fig 3e).

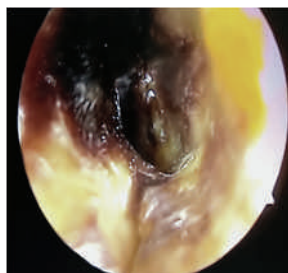


Fig 3 : (a) Diagnostic Nasal Endoscopy – Eschar

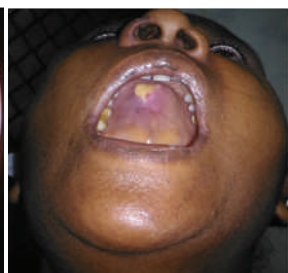


Fig 3 : (b) Palatal Ulcer

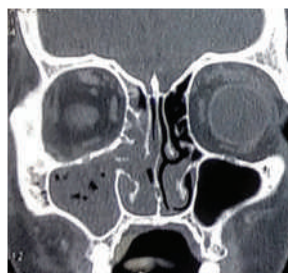


Fig 3 : (c) CT Scan – Pre operative

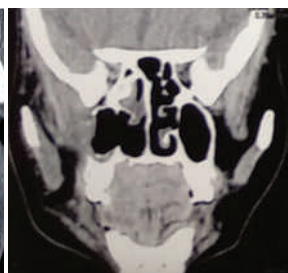

Fig 3 : (d) CT Scan – Post Debridement

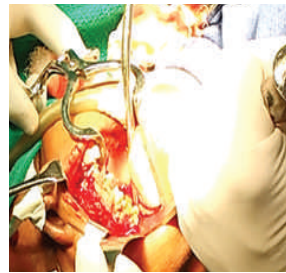


Fig 3 : (e) Per-op – Total Maxillectomy

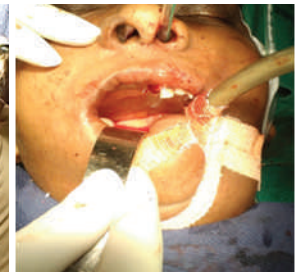

Fig 3 : (f) Post maxillectomy Obturator in situ

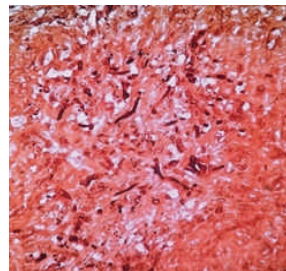


Fig 3 : (g) GMS Stain – Mucormycosis

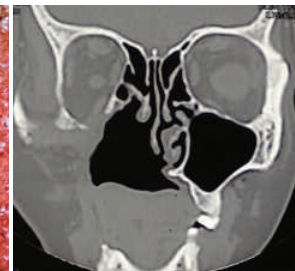

Fig 3 : (h) CT scan – After 6 months of Follow-up

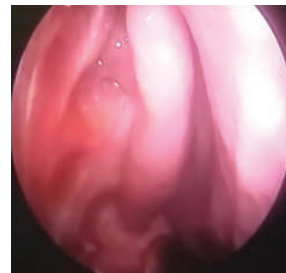


Fig 3 : (i) Nasal Endoscopy after 6 months

Post-operative period was uneventful. Obturator was used to cover the defect in the hard palate region (Fig 3f). After completion of Inj. Amphotericin therapy (cumulative dosage of 2g) patient was discharged in stable condition.

She was followed up at timely intervals - 1 week, 2 weeks, 1 month, 3 months and 6 months post-surgery with nasal endoscopic examination as an office procedure and a radiological investigation (Computed Tomography at 6 months). Patient remains free of disease till date.

Discussion

Prior to the availability of Amphotericin, there were no reported surviving cases of mucormycosis. Even though the frequency of mucormycosis is rare, in recent times it is increasing.⁶ It may be due to increased number of immunocompromised patients or increase in the prevalence of diabetes mellitus or better knowledge of the disease leading to early diagnosis. In our study 37 cases were reported in one single tertiary care centre depicting the increase in the prevalence of mucormycosis.

Pathogenesis⁷ - Both mononuclear and polymorphonuclear phagocytes destroy the organisms by generating oxidative metabolites and cationic peptides defensin.⁸ Hyperglycemia and acidosis impair chemotaxis, adherence and oxidative bursts thus reducing the

effective phagocytic activity of leukocytes. Thus, quantitative or qualitative defects in phagocytosis are the key pathogenesis for mucormycosis. In addition, the acidic pH causes dissociation of iron, causing rapid fungal growth. The fungus has affinity for tunica intima of the blood vessels causing thrombosis which in turn leads to ischaemic tissue necrosis. Thus, a black necrotic eschar is the most typical lesion, but its absence does not necessarily rule out the disease. As mentioned above, the fungus has angioinvasive properties and thus it can disseminate hematogenously to other parts. Perineural spread is also possible.¹⁰

The risk factors for mucormycosis includes diabetes mellitus, haematological malignancy, solid organ transplantation, prolonged corticosteroid therapy, iron overload, desferroxamine therapy, neutropenia, trauma, burns etc.^{11,12} In our study, only 2 out of 37 patients had history of prolonged corticosteroid treatment. 83.7% (31 out of 37 patients) had Diabetes Mellitus. In line with the study by Sujatha et al in 2015, there is a change in trend towards diabetes mellitus as it is the most important factor.^{11,12,13,14} Mucormycosis as the first manifestation of an undiagnosed Diabetes

Mellitus 15 was the feature in 4 patients in our study as quoted by Bhansali et al in her study. Also, the recent control of diabetes and diabetic ketoacidosis^{11,12} was more commonly associated rather than the duration of diabetes. Recent history of admission (nosocomial infection)¹⁶ was present in 20/37 patients which correlates with Chakrabarti et al which states that mucormycosis trend is changing towards nosocomial rather than community acquired infection. Trauma contributed a small share to the etiology.

Like several other studies, nasal symptoms along with facial pain and swelling and ocular symptoms were predominant.¹⁷ Specifically, facial nerve involvement was present in 12 cases (32%) as mentioned by Maes et al in their study.¹⁸ One probable pathway is via the pterygomaxillary region and infratemporal fossa as mentioned in study by Hosseini et al.¹⁹

The diagnosis of mucormycosis is made by clinical features and Histopathological examination and aided by radiology. Histopathology examination shows predominant necro-inflammatory exudates with acute inflammatory cells with broad aseptate cellophane tube-shaped branching filamentous fungal hyphae. While radiological investigation is non-specific, it mainly shows the extent of lesion.²⁰ Histopathological confirmation delays the treatment. But, a typical history/clinical features and a suspicion of mucormycosis by itself facilitates in pointing towards a clinical provisional diagnosis of mucormycosis.

The fungus thrives in devitalized necrotic tissue which cannot be penetrated by systemic antifungals. Also, as there are ischemic and thrombotic changes, the drugs fails to reach the target area. Hence, radical surgical debridement removing all the devitalized tissue is the key to successful treatment. Thus, once a clinical provisional diagnosis of mucormycosis is made, immediate radical surgical debridement²¹ reduces the local fungal load. Simultaneous medical therapy (including systemic antifungals – Inj. Amphotericin and/

followed by Syp. Posaconazole²²) and management of metabolic derangement, improves the patients general condition as well, after which, the patient can be taken up for a more definitive procedure under general or local anaesthesia.

In various studies, the mortality rate was – 60% (Straus et al), 35-40% (H.M. Prado-Calleros et al), 50-80% (Komali Garlapati et al), 52% (Dora E. Corzo-Le´on et al), 46% (Ajay Verma et al). But in our study, in Group – A, where initial radical endoscopic surgical debridement followed by multiple staged surgical procedures were done, the results were the best (20/21 i.e. >95% patients are living free of disease). Whereas in in Group – B, where patients were initially metabolically stabilized and then taken up for surgery, results were not good (5/8 i.e. 63% patients living free of disease). Simple calculation proves that Multiple Staged Surgical Debridement is a significantly better treatment protocol. Most importantly, untreated cases of mucormycosis is extremely fatal, as shown by all the deaths in Group - C.

Conclusion

Management of mucormycosis in our centre was focused on Multiple Staged Debridements rather than a delayed single staged extensive surgery alongside systemic antifungals. Multiple Staged procedures seem to improve the metabolic status of the patients and improves the outcome of the patients.

Authors declare no conflicts of interest.

References

- 1) Paltauf A, Mycosis mucorina in: Virchow's Archiv fur Pathologische Anatomie und Physiologie und fur klinische Medicine. 1885;102(8): 543-64.
- 2) Rees JR, Pinner RW, Hajjeh RA, Brandt ME, Reingold AL. The epidemiological features of invasive mycotic infections in the San Francisco Bay area, 1992-1993: results of population-based laboratory active surveillance. Clin Infect Dis. 1998;27(5):1138-47.
- 3) Roden MM, Zoutis TE, Buchanan WL, Knudsen TA, Sarkisova TA, Schaufele RL, et al. Epidemiology and outcome of zygomycosis: a review of 929 reported cases. Clin Infect Dis 2005;41(5):634-53.
- 4) Chakrabarti A, Das A, Sharma A, Panda N, Das S, Gupta KL et al. Ten years' experience in zygomycosis at a tertiary care centre in India. J Infect. 2001;42(4):261-6.
- 5) Prabhu RM, Patel R. Mucormycosis and entomophthoromycosis: a review of the clinical manifestations, diagnosis and treatment. Clin Microbiol Infect. 2004;10(1):31-47.
- 6) Richardson M. The ecology of the Zygomycetes and its impact on environmental exposure. Clin Microbiol Infect. 2009;15(5):2-9.

- 7) Reddy SS, Rakesh N, Chauhan P, Sharma S. Rhinocerebral Mucormycosis Among Diabetic Patients: An Emerging Trend. *Mycopathologia*. 2015;180(5-6):389-96.
- 8) Spellberg B, Edwards J Jr, Ibrahim A. Novel perspectives on mucormycosis: pathophysiology, presentation, and management. *Clin Microbiol Rev*. 2005;18(3):556-69.
- 9) Ibrahim AS, Spellberg B, Walsh TJ, Kontoyannis DP. Pathogenesis of mucormycosis. *Clin Infect Dis*. 2012;54(1):16-22.
- 10) Sravani T, Uppin SG, Uppin MS, Sundaram C. Rhinocerebral mucormycosis: Pathology revisited with emphasis on perineural spread. *Neurol India*. 2014;62(4):383-6.
- 11) Cunha MA, Nery AF, Lima FP, Diniz Junior, Maciel Neto J, Calado NB et al. Rhinocerebral zygomycosis in a diabetic patient. *Rev Soc Bras Med Trop*. 2011;44(2):257-9.
- 12) Pak J, Tucci VT, Vincent AL, Sandin RL, Greene JN. Mucormycosis in immunochallenged patients. *Journal of Emergencies, Trauma and Shock*. 2008;1(2):106-13.
- 13) Yohai RA, Bullock JD, Aziz AA, Markert RJ. Survival factors in rhino-orbital-cerebral mucormycosis. *Surv Ophthalmol*. 1994;39(1):3-22.
- 14) Ferry AP, Abedi S. Diagnosis and management of rhino-orbitocerebral mucormycosis (Phycomycosis). A report of 16 personally observed cases. *Ophthalmology*. 1993;90(9):1096-104.
- 15) Bhansali A, Bhadada S, Sharma A, Suresh V, Gupta A, Singh P et al. Presentation and outcome of rhino-orbital-cerebral mucormycosis in patients with diabetes. *Postgrad Med J*. 2004;80(949):670-4.
- 16) Arunaloake C, Singh R. Mucormycosis in India: unique features. *Mycoses*. 2014;57(3):85-90.
- 17) Abdollahi A, Shokohi T, Amirrajab N, Poormosa R, Kasiri AM, Motahari SJ et al. Clinical features, diagnosis, and outcome of rhino-orbital-cerebral mucormycosis- A retrospective analysis. *Curr Med Mycol*. 2016;2(4):15-23.
- 18) Meas T, Mouly S, Kania R, Hervé D, Herman P, Kévorkian JP et al. Zygomycosis: an uncommon cause for peripheral facial palsy in diabetes. *Diabetes Metab*. 2007;33(3):227-9.
- 19) Hosseini SM, Borghei P. Rhinocerebral mucormycosis: pathways of spread. *Eur Arch Otorhinolaryngol*. 2005;262(11):932-8.
- 20) Raab P, Sedlacek L, Buchholz S, Stolle S, Lanfermann H, Imaging Patterns of Rhino-Orbital-Cerebral Mucormycosis in Immunocompromised Patients: When to Suspect Complicated Mucormycosis. *Clin Neuroradiol*. 2017;27(4):469-75.
- 21) Vironneau P, Kania R, Morizot G, Elie C, Garcia-Hermoso D, Herman P et al. Local control of rhino-orbital-cerebral mucormycosis dramatically impacts survival. *Clin Microbiol Infect*. 2014;20(5):336-9.
- 22) Manesh A, John AO, Mathew B, Varghese L, Rupa V, Zachariah A et al. Posaconazole: an emerging therapeutic option for invasive rhino-orbital-cerebral mucormycosis. *Mycoses*. 2016;59(12):765-72.