

Case Report

Asymptomatic Large Placental Chorioangioma In A Primigravida

Binu Pattayail *, Swarnapriya K**, Vasantha N Subbiah***

*Assistant Professor, ** Associate Professor, ***Professor & HOD, Department of Obstetrics and Gynaecology, Chettinad Hospital & Research Institute.



Dr. Binu finished her MBBS and MS OG from Bangalore Medical College and Ramaiah Medical College respectively. She also finished her DNB OG . She has keen interest in laparoscopy, so she went on to do a year fellowship in endogynaecology, recognised by MGR University. At present she is an Assistant Professor in Chettinad Hospital and Research Institute.

Corresponding author - Binu P - (binupattayail@gmail.com)

Chettinad Health City Medical Journal 2016; 5(3): 150 - 152

Abstract

Chorioangioma of placenta is a benign angioma of placenta . It usually does not cause any symptoms but sometimes may be associated with adverse maternal and fetal complication especially when it reaches large size. We present a case of large chorioangioma in which there were no maternal or fetal complications. The placental tumor size remained the same throughout pregnancy and an uncomplicated term delivery occurred. Placental chorioangioma got confirmed by macroscopic and histopathological examination.

Key Words: Chorioangioma, Placenta, Large

Introduction

Most common placental tumors are benign in nature and chorioangioma of placenta are the most common among them. They constitute 1% of all pregnancies¹. Most commonly they present as single tumor but they can also be multiple. Chorioangioma literally means abnormal proliferation of new blood vessels from the chorionic tissue¹⁻³.

Placental chorioangioma which are smaller than 5 cm are considered small and generally don't cause any complications. Large tumors cause complications by acting as arteriovenous shunts⁴. The gold standard diagnostic tool in diagnosing placental chorioangioma is Doppler ultrasound¹. Whenever placental chorioangiomas are asymptomatic their management is conservative. In spite of that, aggressive monitoring of pregnancy and fetal condition is suggested to pick up any early maternal and fetal complications.

Case Presentation

26 years old primigravida booked in CHRI a known case of hypothyroidism on treatment, with impaired glucose tolerance on diet control was diagnosed to have a large chorioangioma in growth scan at 32 weeks of size 6x6cm. Patient was followed up with serial growth scan and Doppler twice weekly, and modified biophysical profile twice weekly. No maternal and fetal complications developed throughout pregnancy. Pregnancy was terminated at 38 weeks by elective LSCS in view of large chorioangioma . Alive girl baby of 3.1kg with Apgar 8/10, 9/10 delivered. Placental vascular tumor of 6x7cm attached to the site of cord insertion removed in toto (Fig 1). Prophylactic oxytocics given in view of increased chances of postpartum hemorrhage. Intraoperative and postoperative period uneventful, mother and baby

discharged on post - op 4 day. Histopathological examination revealed chorioangioma with 4 vessels in umbilical cord.

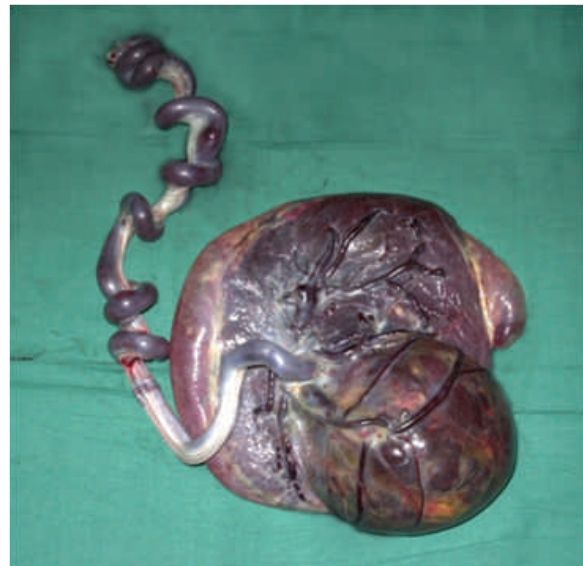

Fig 1 : Gross Appearance Of Chorioangioma

Discussion

Chorioangioma of placenta is benign angioma of chorionic tissue¹. The neoplastic diseases of placenta are divided into - trophoblastic and nontrophoblastic. Nontrophoblastic diseases are almost always benign. Teratoma and chorioangioma fall into the category of nontrophoblastic diseases¹⁻³ . The most common histological type being chorioangioma¹. 1% of histopathological examination of placenta shows chorioangioma (Fig 2). Till date the largest retrospective

study conducted had an evidence of 138 chorioangioma in 22000 placentas examined, which makes the incidence of 0.6%⁵.

Increased incidence of placental chorioangioma is associated with maternal age, diabetes, hypertension, female sex of the baby, first delivery, multiple pregnancies^{6,7}. Chorioangioma starts as early as 16th day of fertilization, although it has not been documented in first trimester⁸. There are three histological patterns of placental chorioangiomas: angiomatous, cellular, degenerated⁹. The angiomatous is commonest histological subtype comprising of numerous capillaries and blood vessels which is surrounded by placental stroma. There is no malignant potential⁵.

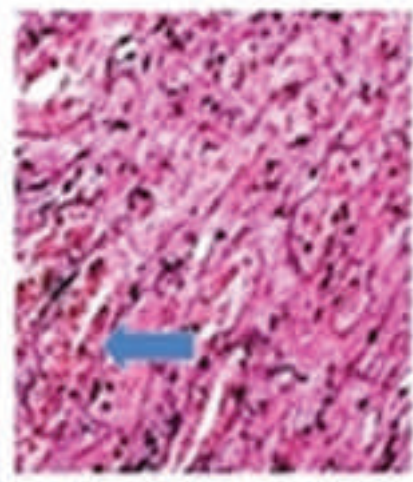


Fig 2: Microscopic examination of chorioangioma

Clinical Features and Complications

Small tumors which are < 5cm are usually asymptomatic and do not cause maternal and fetal complications. Large tumors > 5cm probably cause complications by acting as large arteriovenous shunts. Maternal complications are -preeclampsia, placental abruption, polyhydramnios, preterm labour. Out of these, polyhydramnios and preterm delivery are most common complications, latter caused due to polyhydramnios. Fetal congestive cardiac failure is caused because of increased blood flow through the vascular channels with low resistance acting as an arteriovenous shunt. Other fetal complications are - fetal thrombocytopenia, hemolytic anemia, cardiomegaly, non immunologic fetal hydrops, umbilical vein thrombosis, intrauterine growth restriction, brain infarction, fetal cerebral embolism, and intrauterine and neonatal death¹⁰.

The mechanism of polyhydramnios are - (1) Increased intravascular pressure caused by blood flow obstruction in the tumor near umbilical cord insertion leads to increased transudation into amniotic cavity. (2) Large surface area of enlarged vessels of the tumor also causes increased transudation. (3) Partial placental insufficiency due to shunting of the fetal blood into vessels of placental chorioangioma¹¹.

Ultrasound Diagnosis

The first case of chorioangioma was reported by Clarke in 1978¹¹. Antenatal ultrasound helps in diagnosis and follow up of fetus, hence timely delivery can be done⁸. Gray-scale findings are well-defined echogenic mass which is complex. The mass is different from the rest of placenta, and it protrudes into amniotic cavity near the cord insertion⁸.

The gold standard of diagnosing chorioangioma is Doppler Ultrasound examination. Doppler ultrasound can differentiate chorioangioma from placental teratoma, leiomyoma and blood clot¹². On Doppler, feeding vessel has similar pulsatile flow as of umbilical artery but the flow has low resistance due to arteriovenous shunt¹³(Fig 3). Doppler ultrasound along with fetal echocardiography can diagnose fetuses with cardiac failure. Fetal cordocentesis can be done to diagnose fetal anemia, at the same setting, blood transfusion to fetus can be done¹⁴. Amniotic fluid and serum level of alpha-fetoprotein (AFP) is increased in placental chorioangioma, although it is not specific for placental chorioangioma. AFP can also be increased in various other maternal and fetal conditions¹⁵.

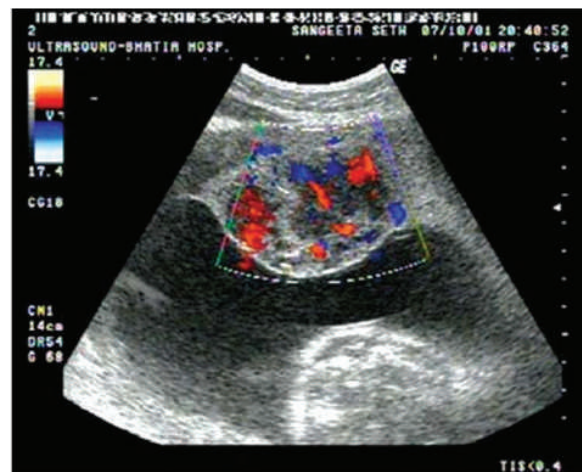


Fig 3: Doppler imaging of chorioangioma

Image source :Pranay R. Shah; Chorioangioma from poly to oligohydramnios - case report from JSAFOG. International scientific journals from Jaypee.

Interventions

Asymptomatic chorioangioma do not require any intervention, follow up with scan and Doppler is adequate. Chorioangioma with complications before the period of viability requires interventions. Various techniques include - fetal transfusions¹⁶, fetoscopic laser coagulation of vessels supplying chorioangioma¹⁷, chemosclerosis with absolute alcohol¹⁸ and endoscopic surgical devascularization. In presence of polyhydramnios therapeutic amniocentesis and maternal indomethacin therapy is recommended. Steroid administration before 34 weeks is given for fetal lung maturity. Management of chorioangioma is usually conservative. Fetoscopic laser ablation of feeding vessel is considered successful even in large chorioangiomas¹⁸.

Differential Diagnosis

Degenerated myomas, placental teratoma, and blood clot are the differential diagnosis of chorioangioma. Doppler demonstrates presence of vascular channels in chorioangioma whereas in others it's absent. Echo pattern of chorioangioma remains same, while of blood clot differs. Myoma is seen on maternal surface, partial mole has diffuse pattern⁸.

Conclusion

Chorioangioma warrants institutional and timely delivery due to high incidence of fetal death. Antenatal ultrasound is used for diagnosis. Doppler is the gold standard to diagnose chorioangioma. Regular follow-up and timely intervention is the key. Our case was monitored with regular ultrasound and Doppler examinations. The size of the chorioangioma remained same. There were no maternal and fetal complications. Histopathological examination confirmed benign nature and no further follow-up was needed.

Very few rare cases of chorangiocarcinoma have been reported and are characterized by atypical trophoblasts with high mitotic index. These cases require follow-up of the mother and infant to exclude malignancy¹³.

References

- 1) Elsayes KM, Trout AT, Friedkin AM, Liu PS, Bude RO, Platt JF, et al. Imaging of the placenta: a multimodality pictorial review. *Radiographics*. 2009;29(5):1371-1391
- 2) Prashanth A, Lavanya R, Girisha KM, Mundkur A. Placental Teratoma Presenting as a Lobulated Mass behind the Neck of Fetus: A Case Report. *Case Rep Obstet Gynecol*. 2012;2012:857230.
- 3) Miliaras D, Anagnostou E, Papoulidis I, Miliara X. Non-trophoblastic tumor of the placenta with combined histologic features of chorangioma and leiomyoma. *Placenta*. 2011;32(1):102-104.
- 4) Bashiri A, Furman B, Erez O, Wiznitzer A, Holcberg G, Mazor M. Twelve cases of placental chorioangioma - Pregnancy outcome and clinical significance. *Arch Gynecol Obstet*. 2002;266(1):53-55.
- 5) Kuhnel P. Placental chorioangioma. *Acta Obstetrica et Gynecologica Scandinavica*. 1933;13:143-145.
- 6) Hirata GI, Masaki DI, O'Toole M, Medearis AL, Platt LD. Color flow mapping and Doppler velocimetry in the diagnosis and management of a placental chorioangioma associated with nonimmune fetal hydrops. *Obstet Gynecol*. 1993;81(5(Pt 2)):850-852.
- 7) Guschmann M, Henrich W, Entezami M, Dudenhausen JW. Chorioangioma – new insights into a well-known problem. Results of a clinical and morphological study of 136 cases. *J Perinat Med*. 2003;31(2):163-169.
- 8) Bracero LA, Davidian M, Cassidy S. Chorioangioma: diffuse angiomatous form. www.thefetus.net. 1993
- 9) Marchetti AA. A consideration of certain types of benign tumors of the placenta. *AJOG*. 1939;38(6):1090.
- 10) Duro EA, Moussou I. Placental chorioangioma as the cause of non-immunologic hydrops fetalis; a case report. *Iran J Pediatr*. 2011;21(1):113-115.
- 11) Asokan S, Chad AK, Gard R. Prenatal diagnosis of placental tumor by ultrasound. *J Clin Ultrasound*. 1978; 6(3):180-181.
- 12) Bromley B, Benacerraf BR. Solid masses on the fetal surface of the placenta: differential diagnosis and clinical outcome. *J Ultrasound Med*. 1994;13(11):883-886.
- 13) Sepulveda W, Aviles G, Carstens E, Corral E, Perez N. Prenatal diagnosis of solid placental masses: the value of color flow imaging. *Ultrasound Obstet Gynecol*. 2000;16(6):554-558.
- 14) Gruca-Stryjak K, Ropacka-Lesiak M, Breborowicz G. Intrauterine blood transfusion in case of placental chorangioma. *Ginekol Pol*. 2011;82(4):304-308.
- 15) Androutopoulos G, Gkogkos P, Decavalas G. Mid-trimester maternal serum hCG and alpha fetal protein levels: clinical significance and prediction of adverse pregnancy outcome. *Int J Endocrinol Metab*. 2013;11(2):102-106.
- 16) Zalel Y, Weisz B, Gamzu R, Schiff E, Shalmon B, Achiron R. Chorioangiomas of the placenta: sonographic and doppler flow characteristics. *J Ultrasound Med*. 2002;21(8):909-913.
- 17) Quintero RA, Reich H, Romero R, Johnson MP, Gonçalves L, Evans MI. In utero endoscopic devascularization of a large chorioangioma. *Ultrasound Obstet Gynecol*. 1996;8(1):48-52.
- 18) Wanapirak C, Tongsong T, Sirichotiyakul S, Chanprapaph P. Alcoholization: the choice of intrauterine treatment for chorioangioma. *J Obstet Gynaecol Res*. 2002;28(2):71-75.