

# Original Article

## Surgical Review of Exploratory Tympanotomy - Facts & Figures

\* Sanjeev Mohanty, \*\*Shameena Shinaz, \*\*P Vijayaprabhu, \*\*Tanuja Panigrahi

\*Professor & HOD, Dept. of ENT, Head & Neck Surgery, Sri Ramachandra University & Hospital, Chennai, India, Director, Dr. Mohanty's Speciality Clinics, Manapakkam, Chennai, India, Chief Consultant, Dept. of ENT, Head & Neck Surgery, \*\* junior Consultant, St. Thomas Hospital, Chennai, India.



Dr. Sanjeev Mohanty currently serves as Professor and Head of Otolaryngology at Sri Ramachandra Medical College. He in addition serves as Chief Consultant at St Thomas Hospital, Chennai. Dr. Mohanty is a Fellow of International College of Surgeons and the European Board of Otolaryngology. He has undergone training in Skull Base Surgery, Cochlear Implantation, Head and Neck Surgery and Neurotology from reputed centres in USA and Germany. He is a reviewer for many National and International journals. He has served as faculty in conferences in India and abroad. His special interests are in Endoscopic Skull Base surgery, Phonosurgery and advanced Head and Neck Surgery.

Corresponding author - [Sanjeev Mohanty \(drsanjeevmohanty@gmail.com\)](mailto:drsanjeevmohanty@gmail.com)

Chettinad Health City Medical Journal 2015; 4(4): 161 - 163

### Abstract

**Background:** A large number of patients with intact membrane and conductive hearing loss continue to remain undiagnosed. An endoscopic tympanotomy provides an alternative technique for diagnosis and also facilitates treatment, thus proving a more cost effective approach. **Methods:** A prospective analysis over a 3 year period of 63 exploratory tympanotomies for conductive hearing loss was performed in patients with intact tympanic membrane. Any cause detected at the time of surgery was treated at the same surgery. Post-operative follow up of the patient was done up to 6 months. **Results:** The most common operative diagnosis was found to be otosclerosis (66%), followed by ossicular disruption, middle ear adhesions, foreign bodies and tympanosclerotic patch. Stapedotomy with prosthesis insertion was the most frequent surgical procedure performed in the series, resulting in effective hearing improvement in immediate post op period. **Conclusion:** Endoscopic tympanotomy serves as an effective diagnostic tool, as well as a treatment option. This study is of value in providing differential diagnosis of conductive hearing loss with an intact tympanic membrane and analyzing the surgical challenges associated with it.

**Key Words:** Exploratory Tympanotomy, Endoscopic Tympanotomy, Conductive hearing loss, Otosclerosis

### Introduction

Diagnosing the cause of conductive hearing loss in an intact tympanic membrane has been a challenge for the otologist over decades. The aetiology for such conditions includes middle ear pathologies like otosclerosis, ossicular chain fixation, tympanosclerosis, middle ear adhesions etc. Some patients present a middle ear problem that can be diagnosed and resolved only by direct inspection. Some times, additional findings can be encountered during exploratory tympanotomy which are of doubtful significance or which may come in the way of correction of the cause of conductive hearing loss<sup>1</sup>. For the surgeons, mastery of tympanotomy requires adequate knowledge about the anatomy and the skill to handle the microscope or the endoscope.

Though microscope has been a boon over the years in the management of ear diseases, the optical properties have remained the same over the period of time<sup>2</sup>. Due to superior optical properties, otoendoscopes are increasingly being used as a diagnostic, surgical and a teaching tool.

### Methodology

**Objective:** To ascertain the efficacy of use of endoscopes in exploratory tympanotomy and to assess the causes for conductive hearing loss in an intact tympanic membrane. **Study design:** Prospective cohort study

**Inclusion Criteria:** Patients with exclusive conductive hearing loss with intact tympanic membrane Patients with mixed hearing loss with Air Bone gap of >20 dB with intact tympanic membrane

**Exclusion Criteria :** Acute middle ear infections, Previous history of ear surgery.

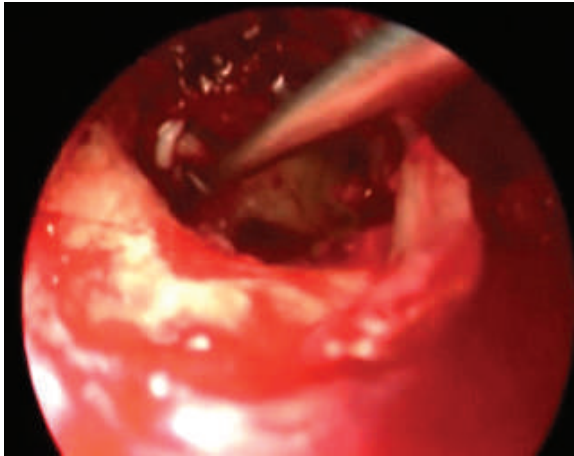
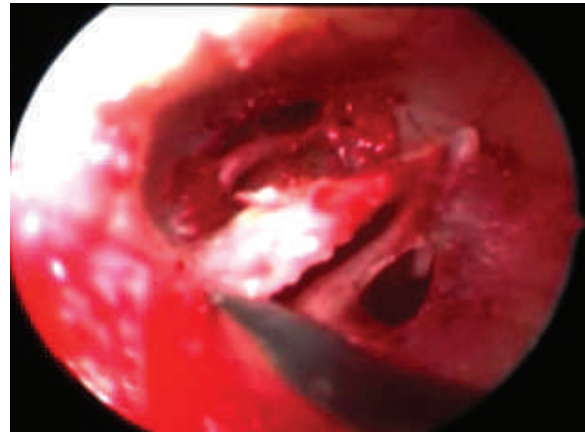
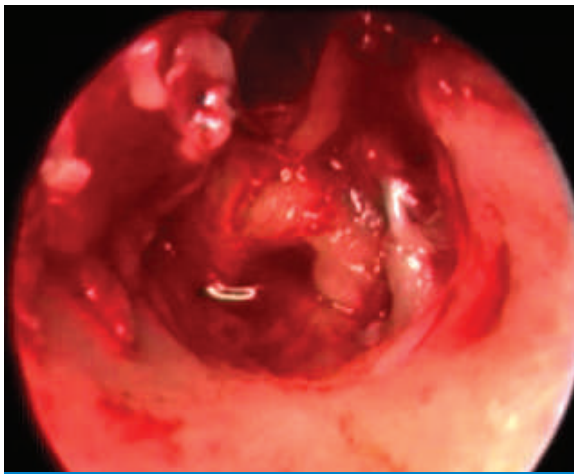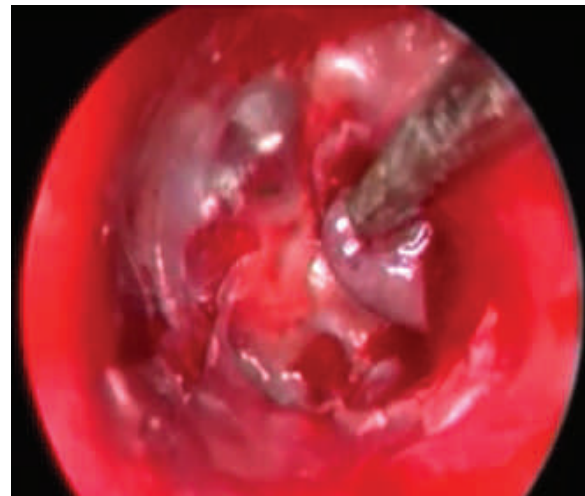
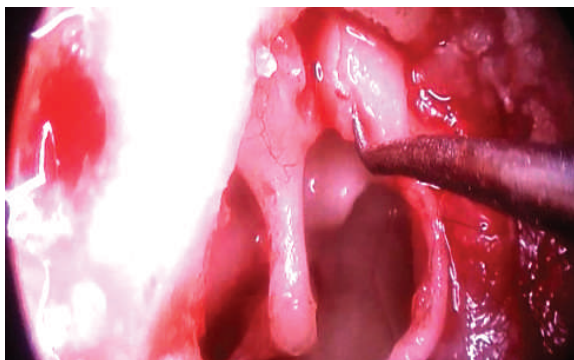
It is a single institution study done by a single surgeon over a period of 3 years. All procedures were standardized through an endo meatal approach. With a follow up period of 6 months. A total of 63 patients were included in the study. All patients were clinically evaluated and were subjected to pure tone audiometry and tympanometry.

### Results

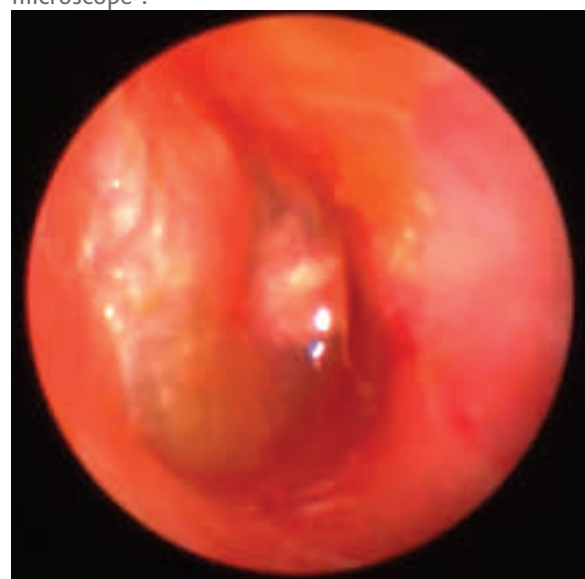Out of 63 patients, 41 were females and 22 were males. 5 patients were between the age group 10-19 years, 10 patients between 20-19 years, 11 between 30 – 19 years, 27 between 20-49 years & 10 patients were above 50 years. In a total of 63 patients, about 41 patients were diagnosed to have otosclerosis. For these patients supra structure of stapes was removed and stapedotomy done with Teflon piston (Fig 1). The hearing of these patients improved post operatively. 4 of them had middle ear adhesions contributing to their conductive.

### Discussion

Conductive hearing loss results from a derangement in

**Fig 1:** Stapedotomy**Fig 4:** TS patch**Fig 2:** Middle ear adhesions**Fig 5:** Glomus tympanum**Fig 3:** IM joint disruption

Ear surgeries have undergone a sea of change with time. The use of endoscope in ontological procedures has been a boon. The advent of better optics has helped and the addition of wide angled endoscopes has widened the scope of surgeries with panoramic view. Otoendoscopes have an advantage of direct, quick and easy access to accessible hidden areas of middle ear cavity which are difficult to view with the use of microscope<sup>3</sup>.

**Fig 6:** Foreign body (grommet) middle ear

the transmission of sound through EAC and the tympano – ossicular chain. There are various etiologies for conductive hearing loss like otosclerosis, fixed ossicular chain, tympanosclerosis, middle ear adhesions etc(Fig2-6). Preoperative clinical assessment remains the cornerstone in diagnosing middle ear disease and determining appropriate treatment. However, in some patients, diagnostic dilemma remains, even after a complete audiological battery.

According to our study, conductive hearing loss due to middle ear pathology was found more in females(65.07%). The fifth decade was the most commonly affected (42.85%). Otosclerosis was the commonest cause of hearing loss in our study followed by ossicular disruption and middle ear adhesions.

Endoscopic view gives a detailed description of anatomic structures, including the middle ear folds and ligaments<sup>2</sup>. Endoscopic ear surgeries have an advantage of comparatively lesser operation time, less bleeding, less post operative time, easy recovery and less hospital stay and better cosmesis<sup>4</sup>. The focussed light, better imaging, excellent resolution, panoramic view, and higher magnification when compared to microscopes are points favouring the use of endoscopes in otology<sup>5</sup>.

The main limitation of endoscopic ear surgery is that it is a single hand cumbersome surgery that may cause arm fatigue for the surgeon<sup>5</sup>. The depth perception is inferior in endoscopic ear surgeries due to its monocular vision when compared to the binocular vision of microscope<sup>6,7</sup>. Meticulous hemostasis is mandatory in endoscopic ear surgery as bleeding can obscure the field<sup>8</sup>. Drilling with an endoscope is challenging and use of multiple instruments is difficult.

## Conclusion

Despite current advances in imaging and audiometry, there is still a necessity to directly visualise the middle ear. Growing trend towards endoscopic surgeries especially in difficult to reach anatomical zones of the middle ear. Though microscopes are here to stay, key benefits offered by the rigid telescope make it a significant alternative.

The authors declare no conflict of interest.

## References

- 1) Se-Hyung Kim, Yang-Sun Cho, Hye Jeong Kim, Hyung-Jin Kim. Operative findings of conductive hearing loss with intact tympanic membrane and normal temporal bone computed tomography. *Eur Arch Otorhinolaryngol.* 2014; 271: 1409-14
- 2) Harugop AS, Mudhol RS, Godhi RA. A comparative study of endoscope assisted myringoplasty and microscope assisted myringoplasty. *Indian J. Otolaryngol. Head Neck Surg.* 2008;60:29-302
- 3) Tarabichi M. Principles of Endoscopic ear surgery. *ENT and Audiology News* 2012;21(3):42-44
- 4) Thiagarajan B, Ulaganathan V. Endoscope assisted myringoplasty. *Otolaryngology online journal* 2012;2(1) www.jorl.net
- 5) Migirov L, Shapiro Y, Horowitz Z, Wolf M. Exclusive Endoscopic Ear Surgery for Acquired Cholesteatoma: Preliminary Results. *Otol Neurotol* 2011;32:433-436.
- 6) Nogueira JF, Cruz DN. Endoscopic 3D Anatomy of the Middle Ear. *Otolaryngol Head Neck Surg.* 2011;145(25):210
- 7) Pothier DD. Endoscopic ear surgery: an introduction, *ENT and Audiology News* 2012;21(3):36
- 8) Mohindra M, Panda NK. Ear surgery without microscope; is it possible, *Indian J Otolaryngol. Head Neck Surg* 2010;62(2):138-141

### Solving the riddle of aging

The problem with getting older is that our face progressively begins to display the ravages of time. Youthfully charming visage is transformed into a dry, wrinkled parchment. In a desperate effort to reclaim that ever receding youth, we do not mind injecting ourselves with toxins (Botox) or going under the scalpel to iron out all those distressing wrinkles. Except in mythology or fiction, there are no elixirs that reverse aging or ensure eternal youth. But, there are genes! First of the genes associated with youthfulness has been identified. It is MC1R. It codes for melanocortin receptor 1. The gene and its product play several roles in colouration of skin, hair and eyes, in inflammation and in repair of DNA. What is more interesting is that the individuals who carry certain variants of this gene are perceived to be several years younger than their true chronological age. This effect was independent of all other factors that affect aging. Of course, there must be other genes associated with aging. We have not found the elixir of eternal youthfulness. But we have taken the first baby step towards understanding the riddle of the aging (Current Biology, doi: <http://dx.doi.org/10.1016/j.cub.2016.03.008>, published 28 April 2016).

- Dr. K. Ramesh Rao