

Case Report

Gigantic Oral Pyogenic Granuloma of the Oral cavity

Gayathri N Goudar*, Manjunath GA **, Subramanya G**, Lakshmi Devi***

*Professor & HOD, **Assistant Professor, *** Reader, Dept of Oral & Maxillofacial Surgery, Sri Siddhartha Dental College & Hospital, Agalakote, Karnataka, India.



Dr. Gayathri Goudar graduated from Government Dental College, Bangalore. She did her postgraduation from Bapuji Dental College & Hospital, Davangere. She has attended and chaired in various National & international conferences, where she has presented papers. She is life member of AOMSI. Her field of interest is maxillofacial trauma and pathologies. She has worked in Sri Siddhartha Dental College & Hospital, (a deemed University) as Professor & HOD. She contributed to the successful DCI approval of first Batch of MDS in Oral & Maxillofacial Surgery. She is currently working as Professor in the Oxford Dental College & Hospital, Bangalore.

Corresponding author - Gayathri Goudar (gayathrigoudar@gmail.com)

Chettinad Health City Medical Journal 2015; 4(3): 150 - 152

Abstract

Pyogenic granuloma although a common oral lesion, has a particular significance, because of its unexpected clinical course. Here we report a gigantic pyogenic granuloma of the left maxillary alveolus extending to involve the hard palate. The lesion was excised under general anaesthesia. This demonstrates an extreme and unusual presentation of a definitely benign lesion.

Key Words: Gigantic Pyogenic Granuloma, General Anaesthesia, Palate, Non Lobular Capillary Haemangioma

Introduction

Pyogenic granuloma (PG) is a kind of inflammatory hyperplasia, which represent a range of nodular growths of the oral mucosa that histologically represent inflamed fibrous granulation tissues. PG is very common non neoplastic tumor – like growth as described by Hüllihen's in 1844¹. Here we are presenting a gigantic non Lobular Capillary Haemangioma type occurring in a 60 year old female patient.

Case Report

A female patient aged 60 yrs reported to our maxillofacial unit with a complaint of painless growth in relation to upper cheek region since 2 yrs. Extraorally it resulted in a diffuse swelling of left middle third of face causing facial asymmetry. It started as a peanut size mass, gradually growing to attain the present size, causing difficulty in mastication and phonation. Clinically presented as a proliferative growth in relation to left maxillary alveolus measuring about 3*4cms in dimension, extending from L22 to L26 crossing the midpalate (Fig 1).

Growth was reddish pink in colour, pedunculated and slightly mobile with no evidence of bleeding on palpation and obliterating the buccal sulcus. Radiologically orthopantomogram and paranasal sinuses showed no evidence of bone loss. The lesion was totally excised under GA (fig 2). Vascular supply of the growth was from greater palatine vessels, which were cauterised and haemostasis achieved. Extraction of 24,25,26,27,28 was done since they are associated with chronic generalised periodontitis. Primary closure of socket done with 3-0 vicryl. Healing was uneventful. Histopathology showed epithelium overlying the edematous connective tissue stroma; it was fibrillar, with immature fibres, moderately cellular with dispersed fibroblasts diagnosed as Pyogenic granuloma (Fig 3,4).

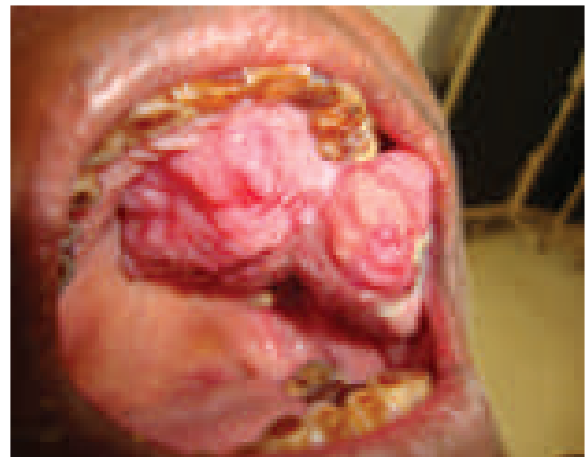

Image 1 - Proliferative Growth In Relation To Left Maxillary Alveolus Measuring About 3*4cms In Dimension.

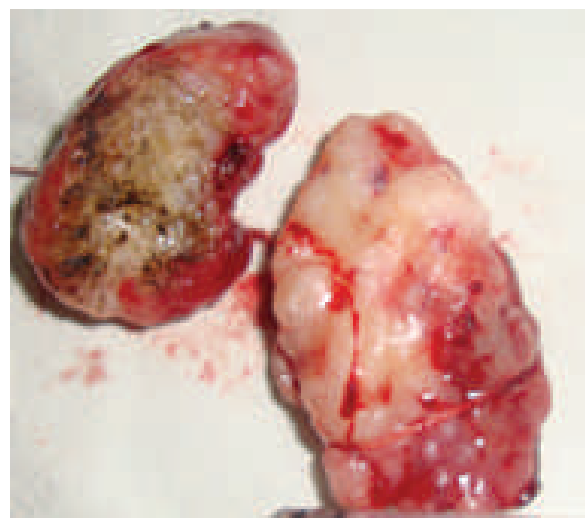

Image 2 - Excised lesion

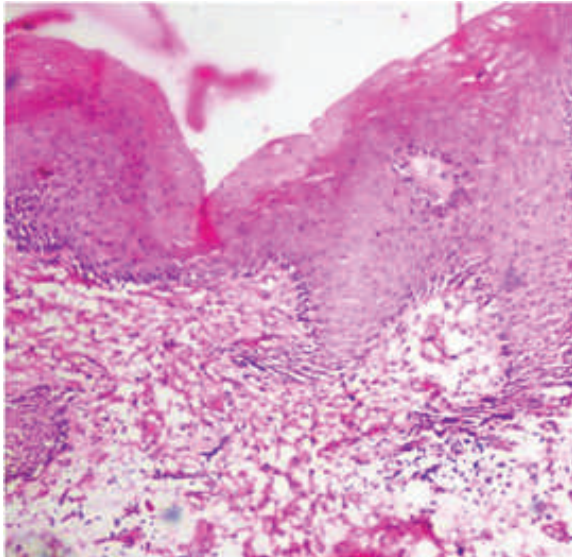


Image 3 - Photomicrograph showing stratified squamous parakeratinised epithelium overlying the connective tissue stroma.

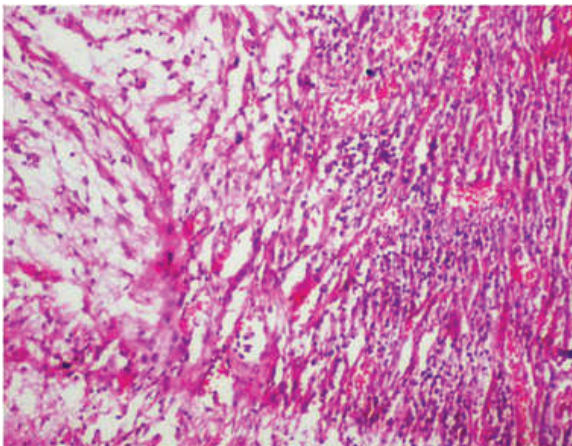


Image 4 - photomicrograph showing deeper connective with lots of blood vessels and extravasated RBCs along with edematous and myxomatous changes. It is fibrillar, with immature fibres, moderately cellular with infiltration of lymphocytes.

Discussion

PG is a benign non-neoplastic mucocutaneous lesion, with the term 'pyogenic' wrongly misquoted². No mechanism for development of PG has so far been defined. However, trauma, hormonal influences, viral oncogenes, have been suspected to act in the pathogenesis. Some consider it to be a reactive tumor like lesion, which arises in response to various stimuli such as chronic low- grade local irritation, traumatic injury, hormonal factors, or certain kinds of drugs like cyclosporine¹⁻⁴. Poor oral hygiene may be the precipitating factor in many patients¹.

Although PGs' may occur in all ages, they predominate in 2nd decade of young adult females, possibly because of vascular effects of female hormones. Oral PGs' are most common gingival tumours, accounting for 75% of all cases caused due to calculus or foreign material within the gingival crevice with 15% occurring on the alveolar part^{1,2,3}.

Clinically, PG manifest as a sessile or pedunculated, resilient, erythematous, exophytic and painful papule or nodule with a smooth or lobulated surface that bleeds easily.

Histologically there are 2 variants of PGs: lobular capillary hemangioma(LCH type) and non-LCH type. The non-LCH type is most commonly associated with etiological factors^{1,5}.

Epivatianos et al, reported two types of PG which are clinically different. They found that LCH PG occurred more frequently as sessile lesion(66%) and non-LCH occurred as pedunculated(77%)⁶. As reported in our case, the lesion was found attached to the alveolus and was pedunculated along with microscopic features suggesting features of non-LCH type. The usual size of PG varies in from few millimetres to centimetres, rarely exceeding 2.5 cm*7, but as reported in our case the lesion was measuring about 3*4 cms hence terming it as gigantic. The surface is ulcerated and friable in most of the cases, with the colour ranging from pink to red to purple, depending on the age of the lesion, but in older patients the lesion tends to be more collagenized and pink^{2,3,8}. Rarely PGs' cause a bone loss¹.

Histopathology

Histologically there are two types of PGs: the 1st type called as LCH, the 2nd type called as non-LCH. Our histopathological report revealed the epithelium overlying the connective tissue stroma(Fig: 2). The connective tissue was edematous with myxomatous changes. Deeper connective showed lots of blood vessels and extravasated RBCs (Fig : 3 and 4). Along with lot of nerve tissue was also seen suggesting the non-LCH type of PG.

Differential Diagnosis

Various differential diagnosis of PGs includes peripheral giant cell granuloma, peripheral ossifying fibroma, metastatic cancer^{1,3} pregnancy tumor⁹, hemangioma¹⁰, Kaposi's sarcoma, angiosarcoma, and non-hodgkin's lymphoma¹.

PGCG is clinically very similar to PG, but histologically in PGCG are the presence of multinucleated giant cells and lack of infection^{1,3}.

POF is also clinically very similar to PG, but it grows to very large size of upto 6cms,commonly seen in pregnant women, but unlike PG this is exclusively found on the gingival and has very less vascularity^{8,3}.

One more important differential diagnosis is Heman-gioma, clinically small lesions cannot be distinguished from PGs. One important feature is it's a developmental disorder, commonly found on the tongue, multinodular and bluish red in color. Compared to PGs, hemangioma has more plump, histiocytoid, endothelial cell proliferation without an acute inflammatory cell infiltrate^{1,10}.

Pregnancy tumors or epulis are mistaken for PGs, but epulis is found towards the end of pregnancy and there is tendency for the lesion to shrink after delivery, is mostly seen confined to interdental papilla^{1,8}.

Kaposi's sarcoma of AIDS can be differentiated from PG histologically due to the presence of dysplastic spindle cells⁷. Angiosarcoma can be distinguished from PG by its lobular growth pattern, well-formed vessels and cytologically bland endothelial cells¹.

Treatment

Excision is the most indicated treatment for PGs' with cauterization of the feeder vessels unless it is in a surgically inaccessible area. It should always be combined with the removal of the causative factors like calculus, periodontally weak teeth, and foreign materials.

Other treatment protocols have also been advocated like the use of Nd:Yag laser irradiation, CO₂ laser, electrodissection, sodium tetradecyl sulphate, sclerotherapy. These treatment protocols are advisable for recurrent lesions. A recurrence rate of 16% has been suggested which may be due to incomplete excision, failure to remove causative factors¹.

Conclusion

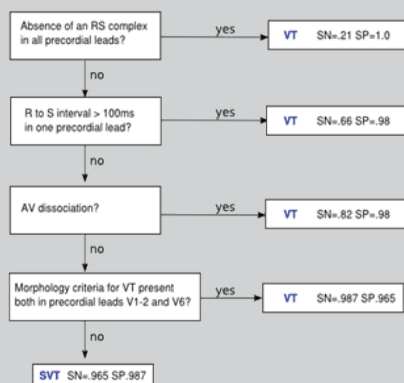
Oral PGS are commonly seen in females mainly pregnant woman and rarely exceeding 2.5cms in size. However in our case it showed an alarming size with occurrence in a non-pregnant woman aged 55-60 years. The histopathology revealed pyogenic granuloma. Therefore large pyogenic granulomas are unusual and should be considered in the differential diagnosis of malignant oral tumour.

References

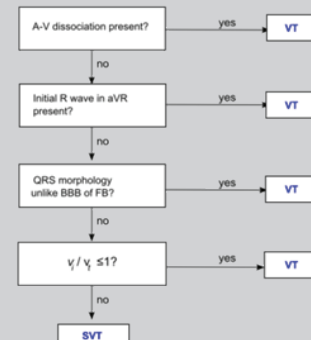
- 1) Jafarzadeh H, Santatkhani M, Mohtasham N. Oral pyogenic granuloma : a review. J Oral Sci. 2006;48(4):167-175.
- 2) Neville BW, Damm DD, Allen CM, Bouquot JE. Oral and Maxillofacial Pathology. 2nd ed. WB Saunders, Philadelphia. 2002:437-495.
- 3) Regezi JA, Sciubba JJ, Jordan RCK. Oral Pathology clinical pathological considerations. 4th ed. WB Saunders, Philadelphia. 2003:115-116.
- 4) Lee L, Miller PA, Maxymiw WG, Messener HA, Rotstein LE. Intraoral pyogenic granuloma after allogeneic bone marrow transplant: Report of three cases. Oral Surg Oral Med Oral Pathol. 1994;78:607-610.
- 5) Nakamura T. Apoptosis and expression of Bax/Bcl-2 proteins in pyogenic granuloma; a comparative study with granulation tissue and capillary haemangioma. J Cutan Pathol. 2000; 27:400-405.
- 6) Epivatianos A, Antoniadis D, Zaraboukas T, Zairi E, Pouloupoulos A, Kiziridou A, Lordanidis S. Pyogenic granuloma of the oral cavity: comparative study of its clinico pathological and immunohistochemical features. Pathol Int. 2005;55:391-397.
- 7) Bouquot JE, Nikai H. Lesions of the Oral cavity. In: Diagnostic surgical pathology of the head and neck. Ed: Gnepp DR. WB Saunders, Philadelphia; 2001:141-233.
- 8) Greenberg MS, Glick M. Burkets oral medicine: diagnosis and treatment. 10th ed. BC Decker, Hamilton. 2003:141-142.
- 9) American Family Physician. Oral health during Pregnancy. <http://www.aafp.org/afp>. April 15, 2008; 77(8).
- 10) Enzinger FM, Weiss SW. Soft tissue tumors. 3rd ed, Mosby, St Louis. 1995:600.

Answer to : Diagnose the condition

Brugada Algorithm



Vereckei Algorithm



By using algorithms, the ECG fits in to diagnosis of SUPRAVENTRICULAR TACHYCARDIA WITH ABBERANCY. It is important to differentiate Ventricular Tachycardia from SVT with aberrancy as management is different for both.