

# Case Report

## Isolated Fourth Nerve Palsy Due to Midbrain Stroke

Subramaniyan K\*, Divya M\*\*

\*Consultant Neurologist, \*\*Junior Resident, Dept. of Neurology, Chettinad Super Speciality Hospital, Chennai, India.



Dr. Subramaniyan is a Consultant in Neurology at CHRI. He finished his graduation and M.D (Internal Medicine) from Stanley Medical College, Chennai and further did his D.M. (Neurology) from Madras Medical College, Chennai. He has worked as an Asst. Professor (Medicine) at SRMC, Chennai and also as a Senior Consultant in Neurology in various hospitals across Tamil Nadu. He has presented many papers at national forums. His areas of interest include infections of the central nervous system and neurological complications following cardiac interventions.

Corresponding author - Subramaniyan K ([drsbra1234@yahoo.co.in](mailto:drsbra1234@yahoo.co.in))

Chettinad Health City Medical Journal 2015; 4(2): 95 - 96

**Key Words:** Trochlear Nerve, Brainstem infarct, Diplopia

### Introduction

Trochlear palsy due to brainstem lesions usually accompanies other neurological deficits. Isolated trochlear palsy can occur in various clinical conditions. Isolated palsy due to brainstem stroke is a very uncommon presentation<sup>1,2,3,4</sup>. Only very few cases have been reported in literature so far.

### Case Report

A 47 year old man, a known diabetic and hypertensive on irregular treatment presented with sudden onset giddiness and double vision while he was climbing down the stairs. No history suggestive of any seizure, loss of consciousness or weakness of limb<sup>5</sup>. No history of any trauma. His neurological examination was normal except left side fourth nerve palsy in the form of left superior oblique palsy (vertical diplopia). No head tilt seen. Patient was advised to take MRI brain with diffusion images with MRA and MRV which showed small acute infarct in the left dorsal para median midbrain (Fig 1,2). All other blood investigations were normal except elevated blood glucose.

Patient was treated with antiplatelets, statins, oral hypoglycemic agents and anti hypertensives. Patient was on regular follow up and showed improvement. After one month of follow up patient was completely relieved of the symptoms.

### Discussion

Fourth nerve palsy can be either congenital or acquired in nature. It can be unilateral or bilateral. Acquired weakness of the muscle leads to vertical diplopia, with a torsional component occasionally. The most common cause of acquired isolated fourth nerve palsy is idiopathic and next is due to head injury. Microvasculopathy due to diabetes, atherosclerosis, or hypertension also may cause isolated fourth nerve palsy. Tumor, aneurysm, multiple sclerosis, or iatrogenic injury may present with isolated fourth nerve palsy. Fourth nerve supplies the superior oblique muscle of the same side. This particular muscle depresses, intorts, and abducts the globe. In acquired lesions of fourth nerve, patients report vertical, torsional, or oblique diplopia.

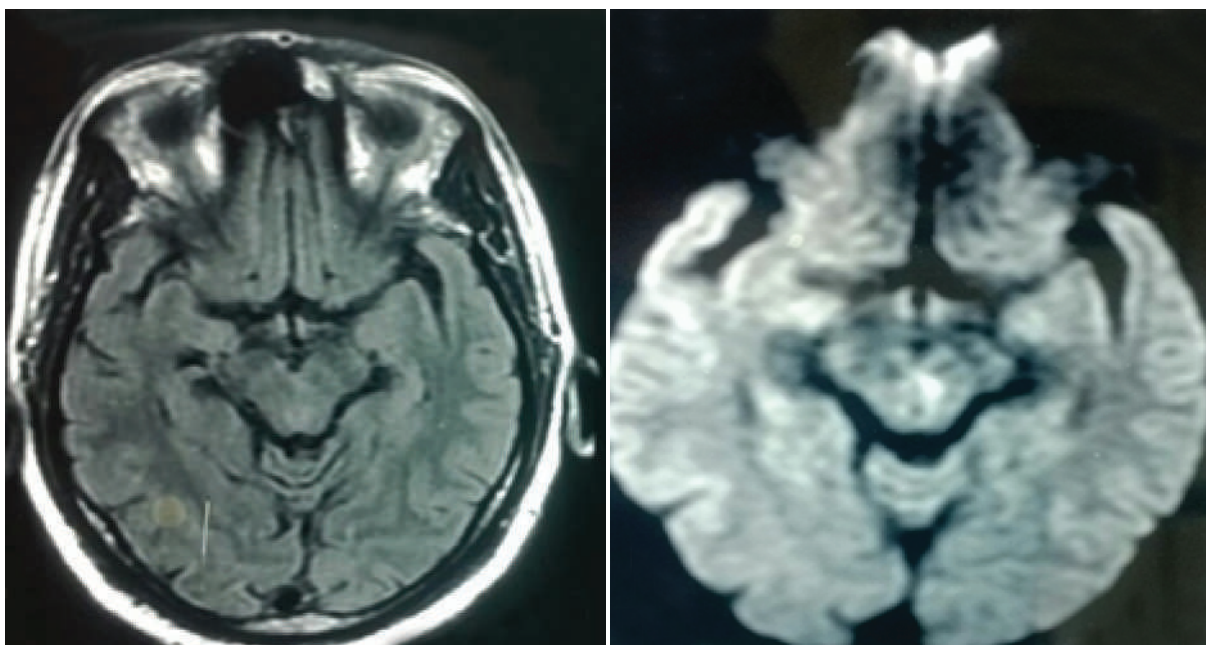


Fig 1 & 2 : MRI showing small acute infarct in left dorsal para median midbrain.

Diplopia is usually of down gaze type and gaze away from side of affected muscle. In case of trauma the presentation is immediate after injury. Torsional diplopia and down gaze horizontal diplopia may be predominant complaints in bilateral palsies. Bielschowsky head-tilt test helps in diagnosing fourth nerve palsy<sup>5</sup>. Diagnosis is purely clinical. MRI Brain with MRA MRV and diffusion weighted images are the ideal choice to look for any lesion. Management depends upon the cause. It is due to micro infarct then it should be treated accordingly along with treatment of co-morbid conditions. Most of the time it is reversible.

## Conclusion

Isolated fourth nerve palsy due to acute brainstem infarct is extremely rare presentation. Patient presents with vertical diplopia only. Early identification and treatment most of the time results in complete relief from the symptoms.

## References

- 1) Kawasaki, Purvin V. Isolated IVth (trochlear) nerve palsy due to basilar artery dolichoectasia. 2006 May;223(5):459-61
- 2) Lee SH, Park SW, Kim BC, Kim MK, Cho KH, Kim JS Isolated trochlear palsy due to midbrain stroke. Clin Neurol Neurosurg. 2010 Jan;112(1):68-71. doi: 10.1016/j.clineuro.2009.08.025. (Epub 2009 Sep 22).
- 3) Makki AA, Newman NJ. A trochlear stroke. Neurology. 2005 Dec 27;65(12):1989.
- 4) Burrell JR, Hayes MW, Saad N. Right trochlear and left oculomotor palsies. J Clin Neurosci. 2009 Nov;16(11):1464 - 1512.
- 5) Hata M, Miyamoto K, Nakagawa S, Horii T, Yoshimura N. Horizontal deviation as diagnostic and prognostic values in isolated fourth nerve palsy. Br J Ophthalmol. 2013 Feb;97(2):180-3. doi: 10.1136/bjophthalmol-2012-302422. (Epub 2012 Nov 10).

## Apathy Is Biologic

In pathologic states like stroke or Alzheimer's, apathy (demotivation or lack of interest) is well known. But when we encounter apathy in a healthy individual, we are likely to dismiss it as an attitudinal problem. Neuroscientists from Oxford University are likely to disagree. In a study involving 40 young volunteers, the researchers used a questionnaire, MRI and a game of offers and rewards to analyse the brain function. Although the more apathetic volunteers were reluctant to choose games with more action, their brains showed more intense activity in the pre-motor cortex than that of the motivated volunteers. Apparently, apathetic individuals have less efficient brain function and have difficulty in converting decisions into actions. The next time you see a student being apathetic in your class room, remember that it is not his attitude that is at fault; but it is his biology! [Cerebral Cortex (doi: 10.1093/cercor/bhv247)]

- Dr. K. Ramesh Rao