

Case Report

Giant Cerebral Arterio-Venous Malformation Excision

M.Krishna Kumar*, K.V.Karthikeyan**, V.G.Ramesh***

*Post Graduate, **Consultant Neurosurgeon, *** Professor & Chief Consultant Neurosurgeon, Chettinad Hospital and Research Institute, Chennai, India



Dr. M. Krishna Kumar is a 2nd year Post-Graduate from the Department of Neurosurgery. He has finished his MBBS from Mahatma Gandhi Medical College & Research Institute, Pondicherry in 2008 and, MS-Gen.Surgery from Meenakshi Medical College, Kancheepuram in 2013. He joined Mch.-Neurosurgery in Chettinad Hospital and Research Institute ever since.

Corresponding author - Dr. M. Krishna Kumar (drkrishnams5@gmail.com)

Abstract

Arteriovenous malformations (AVM) are the most commonly seen surgical vascular lesions. It accounts for about 0.68 per 100000 person-years. Mean age of presentation is about 33-45 years with no sex predisposition. Approximately half of the patients suffer from intracranial haemorrhage (ICH) during their lifetime. In spite of many treatment options available for AVM, surgery is the gold standard treatment though it poses a great challenge. Here we present one such case.

Key Words: AVM's, Craniotomy, Radiosurgery, Embolization.

Chettinad Health City Medical Journal 2014; 3(2): 77 - 79

Introduction

Arteriovenous Malformations (AVMs) are the second most common intracranial vascular malformations. They are believed to be congenital. Multiple AVMs are rare and so are familial AVMs. 90% of AVMs are supra-tentorial. AVMs consist of a bunch of vessels called 'nidus', which is made up of vessels of variable diameter and vessel wall thickness. The AVM may be fed by one or more branches from cortical and deep branches of all major arteries, such as- Anterior cerebral artery, middle cerebral artery and posterior cerebral artery. Brain surrounding the AVM, may show area of gliosis due to ischemia secondary to 'steal' phenomenon. Common presentations of brain-AVM are haemorrhage, epilepsy, progressive neurological deficit, migraine and intractable headache. Clinical signs depend on location of the malformation and the venous drainage.

Case Report

A 61 year old lady presented with complaints of headache, speech disturbance and difficulty in using

right upper limb and lower limb for a duration of 3 weeks. Patient also had a history of difficulty in holding objects with the right upper limb, difficulty in walking (3 week duration) and history of seizures (5 episodes- last episode of seizure was 3 days before admission, started in the right upper limb with secondary generalization and loss of consciousness). On examination, patient had expressive dysphasia with decreased word output with normal comprehension, cranial nerves were intact. Patient had right hemiparesis with power of grade 3 to 4. Deep tendon reflexes were brisk on the right side and plantar was extensor on the right side. CT Angio (Fig.1) and MR Angio (Fig.2 a,b) showed subcortical left temporal lobe arteriovenous malformation fed by middle cerebral artery, posterior cerebral artery and draining veins into superficial middle cerebral vein and transverse sinus. Patient was graded pre-operatively as grade 3 (based on Spetzler and Martin grading system - Table 1). Patient was started on anticonvulsants and other supportive treatments. Patient was offered embolization and excision of AVM or excision of AVM alone, but patient wanted to directly undergo Excision of AVM, hence craniotomy was planned to excise the AVM.

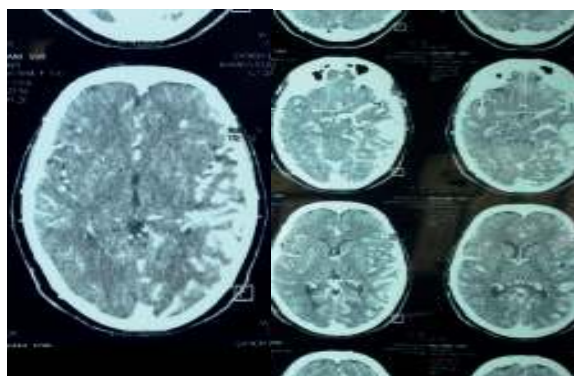


Fig 1 - CT-Angio showing sub cortical left temporal lobe Arteriovenous Malformation.

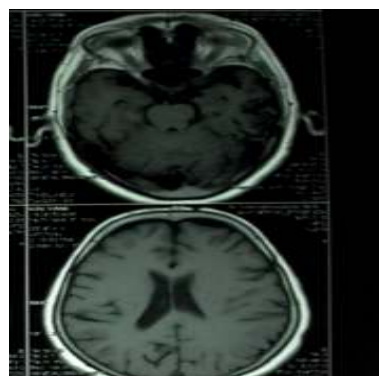

Fig 2a . MRI showing flow voids and nidus suggestive of AVM.

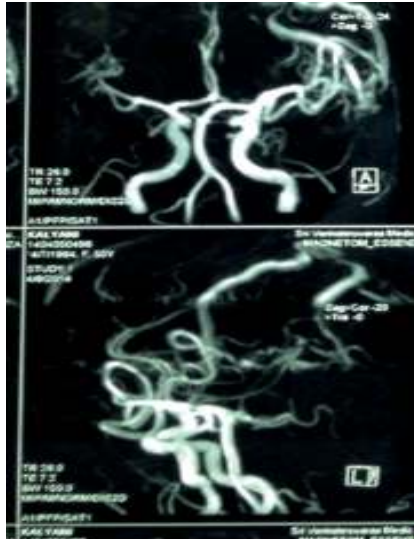

Fig 2b. MRI MR-Angio showing Sub Cortical Left Temporal Lobe AVM of size 4.5cms fed by Middle cerebral artery and Posterior cerebral artery and draining veins into Transverse sinus, no intra-nidal aneurysm seen (Grade III AVM).

Patient was placed in a supine position with face turned to right side, left frontotemperoparietal craniotomy was performed. A large arteriovenous malformation measuring 4.5cms was seen in the left posterior temporal lobe with adhesion to dura which was removed, after identifying the feeders. Arterial feeders were first coagulated and divided while venous feeders were clipped and divided at the end and AVM was excised in toto (Fig.3). Postoperative period was uneventful, patient's deficits improved. Post operative CT scan showed complete excision of AVM (Fig.4).

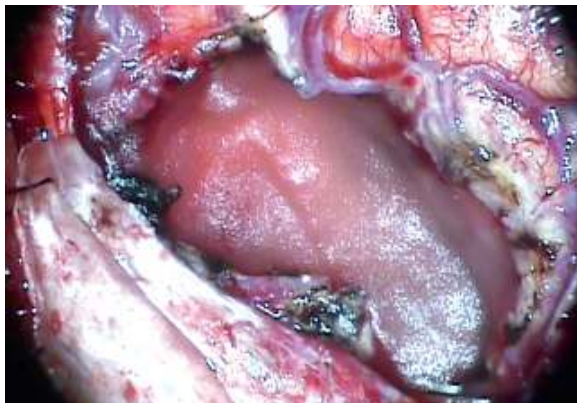

Fig 3. Intra-Operative picture showing complete excision of the AVM.

Discussion

The term arteriovenous malformation is commonly used to describe all types of vascular malformations of the brain. Though numerous classifications have been proposed, widely accepted is the one by McCormik in 1966¹ and is based on the morphology of the competent vessels. This was subsequently modified by him in 1978² as:

- AVM
- Venous angiomas
- Transitional forms
- Cavernous angiomas
- Capillary telangiectasia

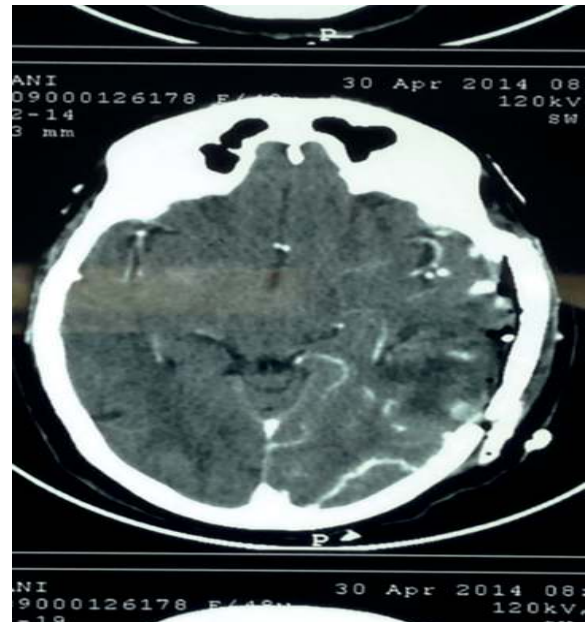


Fig 4. Post-Operative Contrast-CT showing complete excision of AVM.

AVMs are the commonest of these lesions. AVMs are the congenital lesions which develop during the late somite stage, between 4th and 8th week of embryonic life. They rank second to aneurysms among the intracranial vascular lesions that produce subarachnoid haemorrhage. Treatment options available are excisional surgery which is the gold standard, endovascular treatment, radiosurgery and/or combination of the above.

Total surgical resection of an AVM is determined by many factors³-

- Age and neurological status of the patient.
- Size (small, medium, large, giant)
- Location, especially with respect to eloquent areas of the brain.
- Configuration of the nidus.
- Number, size, type and source of arterial feeders.
- Nature of venous drainage (superficial, deep or both) and number of draining veins.
- Haemodynamics of the AVM.

Spetzler and Martin grading system⁴, which takes into consideration- size, venous drainage and eloquence of adjacent brain. A score between 1 - 5 estimates the risk of surgery.

Table 1

1. Size of the AVM
 - Small (less than 3cm)- 1 point.
 - Medium (3-6 cms)- 2 points.
 - Large (more than 6 cms)- 3 points.
2. Eloquence of adjacent brain -
 - Non-eloquent- 0 point.
 - Eloquent- 1 point.
3. Pattern of venous drainage -
 - Superficial only- 0 point.
 - Deep-1 point.

Based on this system:

Grade 1 has good prognosis.

Grade 5 has worst prognosis.

Up to grade 3, excision is the treatment of choice.

Grade 4 and 5 endovascular treatment is the treatment of choice.

A 3-tier classification of cerebral AVMs in which -

Class-A combines Grade I and II AVM`s.

Class-B Grade III AVM`s.

Class-C⁵ combines Grade IV and V AVM`s.

Recommended management is Surgery for Class-A, Multi-Modality treatment for Class-B, and Observation for Class-C.

The first complete surgical excision of cerebral AVM was made by the famous French Surgeon Pean.

Total surgical excision remains the gold standard in the treatment of AVM. The aim of surgical excision is to interrupt the natural history of the disease, and to prevent future haemorrhage, decrease cerebral steal, improve neurological deficits and to achieve seizure control. Main principle of surgical treatment is that arterial feeders are attacked first followed by excision of nidus and finally resection of the draining veins⁶. Care should be taken to preserve veins until the very end of surgery. Large high flow AVM`s are often a surgical challenge for one stage surgical resection.

Current indications for embolization are - Pre-surgical embolization for large or giant cortical AVM⁷ and embolization before radiosurgical intervention to reduce the nidus size. Embolic materials used are divided into solid and liquid agents, solid agents includes microcoils and microballons, liquid agents includes 1-butyl cyano acrylate(BCA), N-butyl cyanoacrylate(NBCA) and ethylene vinyl alcohol(EVAI).

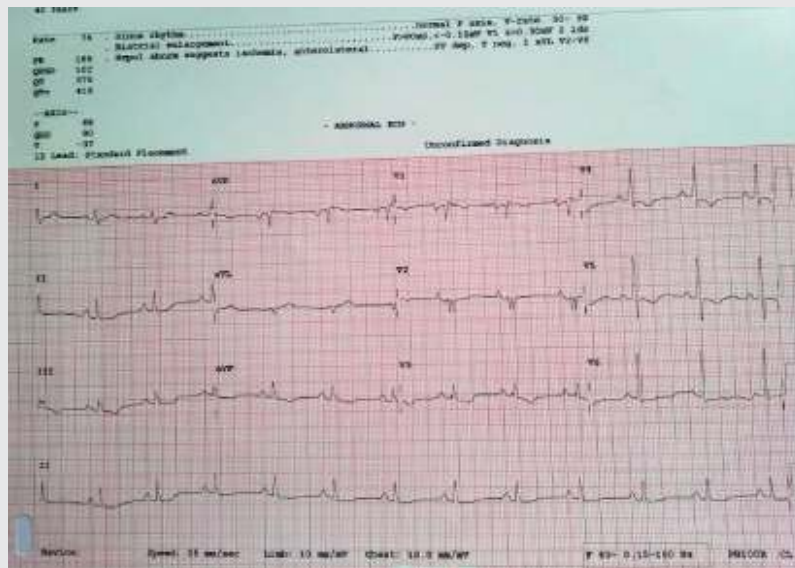
Radiosurgery-gamma knife (Co-60) is useful in small(2-3cms), deeply located inaccessible AVM in eloquent areas of brain with multiple small feeders, in combination with surgery or embolization for large AVM`s, inaccessible or unresectable residual AVM`s and in patients who are not willing for surgery or poor candidates because of concomitant medical illness. Radio surgery is useful; it is successful in treatment of majority of paediatric patients, suffering from AVM`s and morbidity levels are minimal⁸.

References

- 1) Mc Cormick WF. The pathology of vascular (arteriovenous) maldormations. J.Neurosurg. 1966; 24(4) : 807-16.
- 2) Mc Cormick WF. The pathology of Angiomas – In: Fein JM, Flamn ES(Eds) Vascular Surgery IV. New York : Springer Verlag ; 1985:1073.
- 3) Drake CG. Cerebral Arteriovenous Malformations : Considerations for and experience with surgical treatment in 166 cases. Clin.Neurosurg.1979; 26:145-208.
- 4) Spetzler RF, Martin NA. A proposed grading system for arteriovenous malformations. J.Neurosurg. 1986; 65(4): 476-83.
- 5) Robert F.Spetzler, Francisco A.Ponce, A 3-tier classification of cerebral arteriovenous malformations - Clinical article : Journal of Neurosurgery. March 2011; vol.114 (3) : 842-849.
- 6) Yasargill MD (Ed.) MicroNeurosurgery. Stuttgart : Georg Thieme Verlag; 1988.
- 7) Robert F.Spetzler, Neil A.Martin, L Philip.Carter, Richard A.Flour. Surgical Management of Large AVM`s by staged embolization and operative excision. : Journal of Neurosurgery. July 1987; vol.67(1): 17-28.
- 8) Aaron.A.Cohen-Gadal, Bruce E.Pollock. Radiosurgery for arteriovenous malformations in children. Journal of Neurosurgery : Paediatrics. June 2006;vol.104 (6) : 388-391.

Diagnose the condition

A 40 year old male presented with gradually progressive dyspnoea.



Dr. M.Chokkalingam, Consultant Cardiology, CSSH.

Answer in page : 85