

Review Article

Paediatric Stenosing Tenovaginitis of Thumb: Successful Surgical Outcome in Two Children.

Balaji G*, Archit S**, Prashanth MM***, Narayana R****

*Senior Resident, **Junior Resident and Postgraduate student, ***Senior Resident, ****Head of the Department, Department of Orthopaedics, Chettinad Hospital and Research Institute.



Dr. Balaji Govindarajan, presently working as senior resident, department of orthopedics, graduated from university of Mysore in 2000 and obtained his postgraduate diploma in orthopedics from Sri Ramachandra medical college, Porur, Chennai in 2003. He joined this institution in 2006. One of his earlier article was published by the renowned AAOS (American Academy of orthopaedic surgeons) in 2014.

Corresponding author - Dr. Balaji Govindarajan (drbalajirajan@rediffmail.com)

Chettinad Health City Medical Journal 2019; 8(3): 12 - 16

Abstract

Stenosing Tenovaginitis of the long thumb flexor is a rare lesion in children. Also, being commonly referred as 'Congenital Trigger Thumb', its congenital aetiology is controversial and so is the choice of definitive treatment of this condition. Two children who had flexion deformity of the thumb interphalangeal joint underwent surgical correction with excellent outcome and are being presented in this case report.

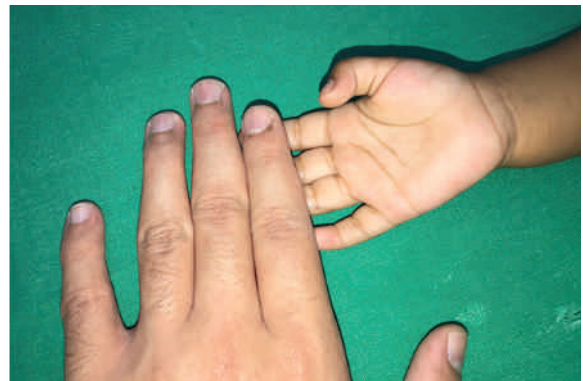
Key Words : Stenosing Tenovaginitis, trigger thumb, A1 pulley.

Introduction

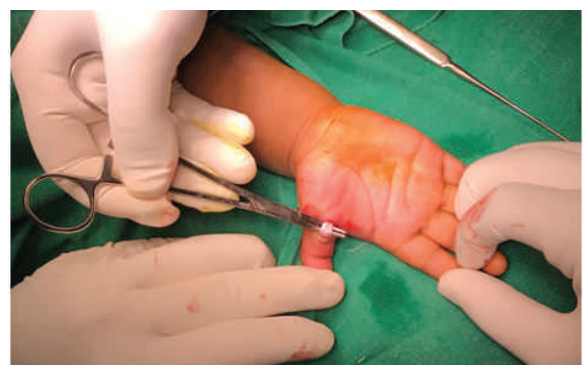Paediatric Stenosing Tenovaginitis of Flexor Pollicis Longus tendon or Congenital Trigger Thumb is rare.^{1,2} Its prevalence is about 2.2% of all paediatric upper limb anomalies.³ The aetiology of this condition remains unclear. In children, though it rarely presents at birth, controversy persists as to whether it is a congenital or an acquired disorder.⁴ Recent studies suggest that it may be acquired.^{5,6} Till date, treatment of this condition also remains controversial. Though surgical decompression of the long flexor of the thumb is considered as a definitive treatment by some authors,^{7,8,9,10} spontaneous resolution has also been reported.¹ Treatment with the use of splints has been described by a few authors.¹¹ The reported success rates of splinting are varied and as such, the patients were initially given at least 3 weeks of a conservative trial which involved splinting of the thumb, along with gentle stretching exercises, which were taught to the parents. There has not been any criteria mentioned in literature priorly, with respect to the duration of the conservative trial to be administered for such patients. We present two cases that were managed surgically with success.

Case Report

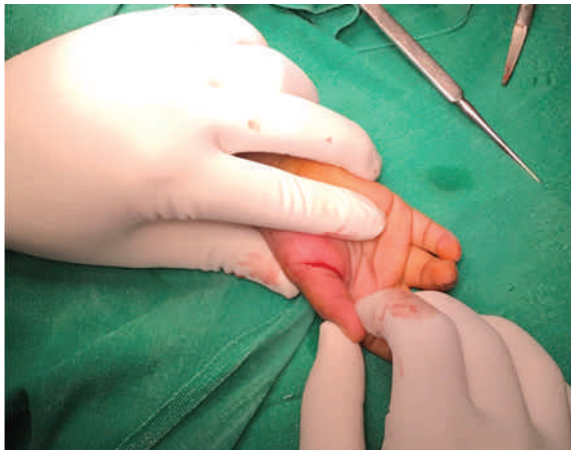Case 1 : A one - and - a - half - year - old female child presented with history of flexion deformity of right thumb noticed by her parents two months earlier. Physical examination revealed a palpable nodule, on the palmar aspect, overlying the metacarpal head. The nodule was not tender. There was a fixed flexion deformity of the interphalangeal joint of about 30 degrees [Figure 1].



Following the patient's visit to our OPD, a trial period of 3 weeks was observed, and no improvement was noted. Thus surgical decompression of the long flexor was done through a transverse incision along the flexor crease at the metacarpophalangeal joint. Complete division of the thickened A1 pulley along its entire length was performed and adequate decompression of Flexor Pollicis Longus tendon was confirmed by lifting the tendon through the incised wound [Figure 2].



The interphalangeal joint regained full extension instantly [Figure 3].



No splint was given postoperatively, and active movements were encouraged. At 6 months post-surgery, there was no recurrence and full motion at Interphalangeal joint was possible.

Case 2 : A three-year-old female child presented with similar flexion deformity of the right thumb that was observed by her parents almost a year back. Prior to their consultation with us, the child had been through a trial period of observation for more than six months with no signs of improvement and another brief period of splinting. On examination, this child had a fixed flexion deformity of 45 degrees with a mildly tender nodular swelling over the corresponding metacarpal head. The thickened A1 pulley was divided to decompress the tendon of Flexor Pollicis Longus resulting in immediate and complete correction of flexion deformity of the interphalangeal joint. At two-and-a-half years post-surgery follow up, the child had excellent thumb function and no recurrence.

Discussion

Though, congenital trigger thumb has been rarely reported to present itself at birth, a congenital or hereditary cause has been proposed by some.^{12,13} Failure to notice the deformity at birth may be due to the flexion attitude of the thumb in a neonate which is normal until the age of three months.⁷ Also, the frequent exclusion of routine thumb examination in a neonate may delay the diagnosis.⁷ Later, during the first year of life when grasping activities are started by the child, the disability may be masked because of Metacarpo-phalangeal and Carpometacarpal joint compensation.⁷ These may be the reasons for late presentation of both of our patients.

It is also noteworthy to mention, due to the uncommon nature of this ailment, there has not been enough research on this topic, hence there was no established scale, which was used by our team in order to assess the outcome. The patients were clinically assessed during their subsequent follow-up visits to the Department of Orthopaedics outpatient department.

The word 'Trigger' is frequently used wrongly to refer this condition because snapping almost never occurs in the paediatric population who usually present with a flexion deformity of the Interphalangeal joint of the thumb.⁶ Our patients too had flexion deformities of the thumb Interphalangeal joint at the time of initial presentation.

We decided to proceed with surgical management, because, in literature, there is no definitive safe period of observation for spontaneous recovery to occur. Moreover, treatment with splinting is impractical and not effective in young children.¹⁴ Delaying the treatment beyond the age of three years may result in residual joint contracture as indicated by some authors.^{7,15} In both our patients, we succeeded in achieving adequate release of the A1 pulley which prevented recurrence. We also preserved the oblique distal pulley that prevented bow-stringing of the Flexor Pollicis Longus tendon as described by Bayne and Costas.¹⁶

Conclusion

Till date, uncertainty exists about the chances of spontaneous recovery and if any delay in surgical decompression would result in permanent deformity. Our case report will help both surgeons and parents to make decision in favour of surgical treatment. Operative release of the A1 pulley of the thumb restores Interphalangeal joint movement, prevent recurrence and therefore is a reliable treatment option in the management of Paediatric Stenosing Tenovaginitis.

References

- 1) Dinham JM, Meggitt DF. Trigger thumbs in children: a review of the natural history and indications for treatment in 105 patients. *J Bone Joint Surg Am.* 2000;82:736-8.
- 2) Skov O, Bach A, Hammer A. Trigger thumbs in children: a follow-up study of 37 children below 15 years of age. *J Hand Surg.* 1990;15:466-7.
- 3) Flatt AE. The care of congenital hand anomalies. 2nd ed. St. Louis: Quality Medical Publishing; 1994:59-60.
- 4) Goo HB, Ji HK, Moon SC. The natural history of Paediatric Trigger Thumb. *J Bone Joint Surg Am.* 2008;90: 980-5.
- 5) Rodgers WB, Waters PM. Incidence of trigger digits in new borns. *J Hand Surg.* 1994 ;19 (3) : 364-8.
- 6) Slakey JB, Henrikus WL. Acquired thumb flexion contracture in children: congenital trigger thumb. *J Bone Joint Surg Br.* 1996;78:481-3.
- 7) Ger E, Kupcha P, Ger D. The management of trigger thumb in children. *J Hand Surg.* 1991 ;16 : 944-7.
- 8) Van GF. Familial trigger thumb in children. *Hand.* 1982;14:56-8.

- 9) Fahey JJ, Bollinger JA. Trigger-finger in adults and children. *J Bone Joint Surg Am.* 1954;36:1200-18.
- 10) White JW, Jensen WE. Trigger thumb in infants. *AMA Am J Dis Child.* 1953;85:141-5.
- 11) Nemoto K, Nemoto T, Terada N, Amako M, Kawaguchi M. Splint therapy for trigger thumb and finger in children. *J Hand Surg.* 1996;21:416-8.
- 12) Gharib R. Stenosing tenovaginitis (trigger-finger). *Journal of Pediatrics.* 1966;69: 294-5.
- 13) Van GF. Familial trigger thumb in children. *The Hand.* 1982;14(1):56-8.
- 14) Mccarroll HR. Congenital flexion deformities of the thumb. *Hand Clin.* 1985;1:567-75.
- 15) Tachdjian MO. Trigger thumb. In: Tachdjian MO. *Pediatric orthopaedics* Philadelphia: WB Saunders Co. 1990:272-3.
- 16) Bayne LG, Costas BL. Malformations of the upper limb. In: Morrissy RT. Lovell and Winter's *pediatric orthopaedics*. Philadelphia: JB Lippincott Co. 1990:563-609.
- 17) Baek GH, Kim JH, Chung MS, Kang SB, Lee YH, Gong HS. The natural history of pediatric trigger thumb. *J Bone Joint Surg Am.* 2008;90(5):980-5.