

Case Report

Bilateral Hip Fractures in a HIV patient with Anti-Retroviral Therapy-Induced Fanconi Syndrome

Balaji G*

*Senior Resident, Department of Orthopedics, Chettinad Hospital & Research Institute, Chettinad Academy of Research & Education, Chennai, India.



Dr. Balaji Govindarajan, presently working as senior resident, department of orthopedics, graduated from university of Mysore in 2000 and obtained his postgraduate diploma in orthopedics from Sri Ramachandra medical college, Porur, Chennai in 2003. He joined this institution in 2006. One of his earlier article was published by the renowned AAOS (American Academy of orthopaedic surgeons) in 2014.

Corresponding author - Dr. Balaji Govindarajan (drbalajirajan@rediffmail.com)

Chettinad Health City Medical Journal 2017; 6(4): 171 - 173

Abstract

Here I report about a 49 years old HIV positive male patient who developed Anti-Retro viral Therapy-induced Fanconi Syndrome and consequently had bilateral pathologic neck of Femur fractures. I suggest that the retro viral infection together with the long-term usage of anti-retroviral drugs may have contributed to the patient's pathologic fractures by aggravating bone demineralisation. This case highlights the importance of monitoring not only for renal impairment but also for bone disease in patients receiving Highly Active Anti-Retroviral Therapy (HAART).

Key Words: Anti-Retroviral Therapy, Fanconi's Syndrome, Bilateral hip fracture, Osteoporosis.

Introduction

Infection with HIV affects almost every organ and system including bone showing a very complex pathogenesis.¹ The Anti-Retroviral Therapy (ART) using a combination of multiple drugs that acts on various viral targets is known as Highly Active Antiretroviral Therapy (HAART). HAART has significantly improved the prognosis in HIV infected subjects.² HAART is well known to be associated with several metabolic derangements, including lipodystrophy, insulin resistance, diabetes and dyslipidemia, especially on long-term usage.³ Rapid deterioration in bone mass, osteopenia and osteoporosis, have been documented in HIV-infected individuals, especially in men in their middle age, with variable prevalence rates.^{4,5} Bone loss has been well noted during the course of HIV infection and this has been a vital problem in the management of HIV infected patients especially when considering the risk of developing a pathological fracture.⁶

Background on HAART-related Nephropathy and its effect on bone metabolism

HAART-induced nephrotoxicity may manifest as Acute Kidney Injury (AKI), Chronic Kidney Disease (CKD), and proximal tubulopathy, like Fanconi Syndrome, hypophosphatemia, and reduced bone mineral density (BMD).⁷ Fanconi syndrome is a proximal tubular disorder which can manifest itself either partially or completely. In its complete form it is associated with renal tubular acidosis, glycosuria with normal blood glucose, aminoaciduria, tubular proteinuria and hypouricemia as a consequence of uricosuria.⁸ Other manifestations of proximal tubular injury in these patients are osteomalacia and decreased bone mass due to phosphate loss in urine and/or calcitriol deficiency, because the mitochondria in proximal tubules are sites of synthesis of calcitriol.⁸

Also, Anti-Retroviral Therapy, especially Tenofovir Disoproxil Fumarate lowers tubular reabsorption of vitamin D-binding protein.⁸

Case Report

A 49 year old HIV infected male patient presented to me with bilateral hip pain for a duration of 8 months, which was gradually worsening. The pain had worsened in the last one month making him almost bedridden. He was on Highly Active Anti-Retro viral Therapy (HAART) with Tenofovir Disoproxil Fumarate 300mg, Efavirenz 600mg and Lamivudine 300mg, for the past 4 ½ years.

On examination, he was moderately built and nourished. Attempted movements of both hip joints were extremely painful. No abnormality was found on clinical examination of other systems.

His pelvis X-ray taken at the time of onset of hip pain was normal (Fig.1). His Xray at the time he presented to me, that is, 8 months following the onset of symptoms showed displaced fracture Neck of Femur bilaterally

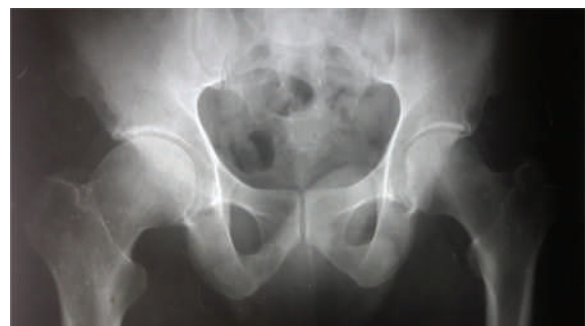

Fig 1: X-ray pelvis taken at the time of onset of hip pain

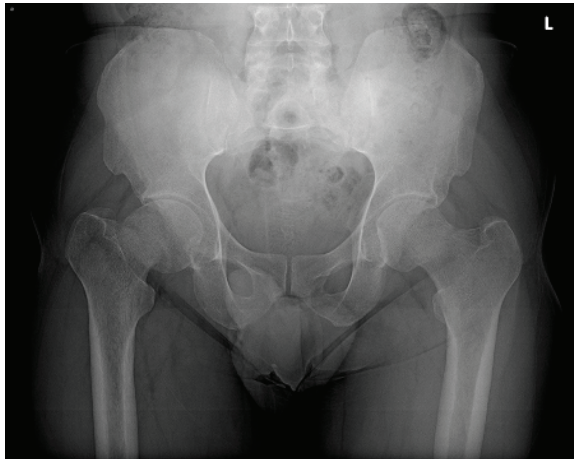


Fig 2: X-ray pelvis showing displaced fracture Neck of Femur bilaterally with generalised osteopenia

with generalised osteopenia (Fig 2). Further laboratory testing revealed elevated serum creatinine (1.63 mg/dL), elevated Alkaline phosphatase (345 U/L), hypouricemia (1.9 mg/dL), normal blood glucose (90 mg/dL) and low Vitamin D. His urine analysis showed uricosuria (59 mg/dL), glycosuria and proteinuria (245.2mg/dL) with urinary micro albumin 185.87 mg/dL. Patient's Arterial Blood Gas analysis revealed metabolic acidosis with compensatory respiratory alkalosis supporting the diagnosis of Fanconi Syndrome. Dual Energy X-ray Absorptiometry of the lumbar spine measured low bone mass with a T-score of -2.3

Discussion

Though bone loss is the most common skeletal manifestation found in HIV-infected patients,^{9,10} major pathological bilateral hip fractures has never been reported previously in literature. The risk Osteopenia increased to 6.4 times and the prevalence of osteoporosis increased to 3.7 times in HIV infected individuals when compared with individuals not infected with HIV¹¹ and the presence of osteoporosis increased 2.4 times in HAART treated patients compared with individuals not on HAART.¹¹

The physiological balance between osteoblasts and osteoclasts is the most crucial factor in determining a good bone mass (Fig. 3), which depends on the perfectly regulated bone remodelling characterized by osteoclastic bone resorption and osteoblastic bone formation.¹² An impairment of this balance in osteoblast-osteoclast interaction occurs resulting in preferential bone resorption in diseases such as infection, hormonal, immunological and metabolic disorders, which compromises both bone mass and structure leading to increased bone fragility and risk of fractures.

There is sufficient evidence to suggest that HIV proteins increase osteoclastic activity¹³ and inhibit bone formation by promoting osteoblast apoptosis.^{14,15} Furthermore, elevated tumour necrosis factor (TNF) increases osteoclast-mediated bone resorption without a significant increase in bone formation.¹⁶ Tenofovir Disoproxil Fumarate affect bone indirectly through proximal tubule injury, resulting in increased urinary phosphate excretion and increased bone

turnover.¹⁷ The drug, Efavirenz affect the bone density indirectly through alterations in vitamin metabolism.¹⁸⁻²¹

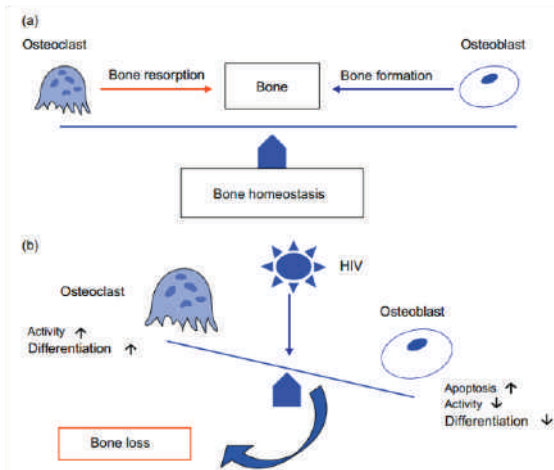


Fig 3: Physiology of Bone homeostasis

Conclusion

Reduction in bone mass is a well-documented and a significant complication of HIV infection. The introduction of HAART has changed the course of the disease, which was once fatal and has considerably prolonged the life expectancy of patients infected with HIV. Hence, HIV/HAART-related bone loss is also sure to increase.

Therefore, antiretroviral therapy must be combined with early detection and efficient management of HIV/HAART induced skeletal disease to lessen the risk of osteoporosis and consequent fractures in these patients. I also recommend periodic assessment of renal function for early recognition of renal tubular dysfunction in HIV-infected patients on HAART. Also required is further research for better understanding of the mechanisms of bone loss that would permit precise interventions to prevent HAART-induced bone loss.

References

- 1) Levy JA. HIV pathogenesis: 25 years of progress and persistent challenges. *AIDS*. 2009; 23(2):147-60.
- 2) Palella FJ, Delaney KM, Moorman AC, Loveless MO, Fuhrer J, Satten GA, et al. Declining morbidity and mortality among patients with advanced human immunodeficiency virus infection. HIV outpatient study investigators. *N Engl J Med*. 1998;338(13):853-60.
- 3) Carr A, Samaras K, Burton S, Law M, Freund J, Chrisolm DJ, et al. Asyndrome of peripheral lipodystrophy, hyperlipidemia and insulin resistance in patients receiving HIV protease inhibitors. *AIDS*. 1998; 12(7):F51-8.
- 4) Tebas P, Poxderly WG, Claxton S, Marin D, Tantisiriwat W, Teitebaum SL, et al. Accelerated bone mineral loss in HIV-infected patients receiving potent antiretroviral therapy. *AIDS*. 2000;14(4):F63-7.

- 5) Knobel H, Guelar A, Valecillo G, Nogues X, Diez A. Osteopenia in HIV-infected patients: Is it the disease or is it the treatment? *AIDS*. 2001;15(6):807-8.
- 6) Arnsten JH, Freeman R, Howard AA, Floris-Moore M, Lo Y, Klein RS. Decreased bone mineral density and increased fracture risk in aging men with or at risk for HIV infection. *AIDS*. 2007;21(5):617-23.
- 7) Karras A, Lafaurie M, Furco A, Bourgarit A, Droz D, Sereni D, et al. Tenofovir-related nephrotoxicity in human immunodeficiency virus-infected patients: three cases of renal failure, fanconis syndrome, and nephrogenic diabetes insipidus. *Clin Infect Dis*. 2003;36(8):1070-73.
- 8) Fernandez-Fernandez B, Montoya-Ferrer A, Sanz AB, Sanchez-Nino MD, Izquierdo MC, Poveda J, et al. Tenofovir Nephrotoxicity: 2011 Update. *AIDS Res Treat*. 2011;2011:354908.
- 9) Serrano S, Marinoso ML, Soriano JC, Rubies-Prat J, Aubia J, Coll J, et al. Bone remodeling in human immunodeficiency virus infected patients. A histomorphometric study. *Bone*. 1995;16(2):185-91.
- 10) Mondy K, Tebas P. Emerging bone problems in patients infected with human immunodeficiency virus. *Clin Infect Dis*. 2003;36(2):S101-5.
- 11) Brown TT, Qaqish RB. Antiretroviral therapy and the prevalence of osteopenia and osteoporosis: a meta-analytic review. *AIDS*. 2006;20(17):2165-74.
- 12) Matsuo K, Irie N. Osteoclast-osteoblast communication. *Arch Biochem Biophys*. 2008;473(2):201-9.
- 13) Fakruddin JM, Laurence J. HIV-1 Vp enhances production of receptor of activated NF-kappaB ligand (RANKL) via potentiation of glucocorticoid receptor activity. *Arch Virol*. 2005;150(1):67-78.
- 14) Borderi M, Gibellini D, Crignis ED. HIV-1 Induces apoptosis in primary osteoblasts: an alternative mechanism in the development of osteopenia and osteoporosis: In Program and abstracts of the 15th Conference on Retroviruses and Opportunistic Infections. 2009.
- 15) Gibellini D, De Crignis E, Ponti C, Cimatti L, Borderi M, Tschon M, et al. HIV-1 triggers apoptosis in primary osteoblasts and HOBIT cells through TNFalpha activation. *J Med Virol*. 2008;80(9):1507-14.
- 16) Bismar H, Diel I, Ziegler R, Pfeilschifter J. Increased cytokine secretion by human bone marrow cells after menopause or discontinuation of estrogen replacement. *J Clin Endocrinol Metab*. 1995;80(11):3351-55.
- 17) Fux CA, Rauch A, Simcock M, Bucher HC, Hirschel B, Opravil M, et al. Tenofovir use is associated with an increase in serum alkaline phosphatase in the Swiss HIV Cohort Study. *Antivir Ther*. 2008;13(8):1077-82.
- 18) Ellfolk M, Norlin M, Gyllensten K, Wikvall K. Regulation of human vitamin D(3) 25-hydroxylases in dermal fibroblasts and prostate cancer LNCaP cells. *Mol Pharmacol*. 2009;75(6):1392-9.
- 19) Fabbriciani G, De Socio GV. Efavirenz and bone health. *AIDS*. 2009;23(9):1181.
- 20) Herzmann C, Arasteh K. Efavirenz-induced osteomalacia. *AIDS*. 2009;23(2):274-5.
- 21) Landriscina M, Altamura SA, Roca L, Gigante M, Piscazzi A, Cavalcanti E, et al. Reverse transcriptase inhibitors induce cell differentiation and enhance the immunogenic phenotype in human renal clear-cell carcinoma. *Int J Cancer*. 2008;122(12):2842-50.