

Case Report

Uterine Papillary Serous Carcinoma

Sathiya S*, Famida A M**, Vijayalakshmi K**, Sailatha R*, Renuka S***

*Associate Professor, **Professor, ***Assistant Professor, Department of Obstetrics and Gynaecology, Chettinad Hospital & Research Institute, Chennai, India.



Dr.Sathiya.S is an undergraduate from Mahatma Gandhi Medical College and Research Institute, Puduchery. She completed her post graduation (MD) in Obstetrics and Gynaecology from Raja Muthiah Medical College and Research Institute, Annamalai University. She is presently working as an Associate Professor in Obstetrics and Gynecology department, Chettinad Hospital & Research Institute, Chennai, India.

Corresponding author - Sathiya S - (s.sathiya.dr@gmail.com)

Chettinad Health City Medical Journal 2016; 5(3): 140 - 143

Abstract

Uterine papillary serous carcinoma is a distinct subtype of endometrial carcinoma by its histological features exhibiting papillary architecture, poor differentiation and advanced stage when the patient presents initially. Uterine papillary serous carcinoma(UPSC) comprises lesser than 10% of all endometrial cancers, it is the most intrusive subtype of endometrial carcinoma. This is a case report of a 70 year old symptomatic nulliparous woman, in whom endometrial biopsy revealed uterine papillary serous carcinoma.

Key Words: Postmenopausal, Endometrial Carcinoma, Papillary Serous.

Introduction

Uterine serous carcinoma(USC), also known as uterine papillary serous carcinoma (UPSC) and uterine serous adenocarcinoma, is an uncommon form of endometrial cancer which is usually seen in postmenopausal women.¹ Uterine papillary serous carcinoma(UPSC) comprises lesser than 10% of all endometrial cancers, it is the most intrusive subtype of endometrial carcinoma.² It is diagnosed on endometrial biopsy, performed in women with post-menopausal bleeding. Endometrial hyperplasia or hormonal therapy is not an origin for UPSC. It usually occurs in patients with endometrial atrophy and is classified as type II endometrial cancer.¹

Uterine papillary serous carcinoma (UPSC) shares typical pathological features, genetic features and clinical features with Mullerian origin of other serous cancers. Papillary serous is the most frequent histological type of ovarian tumor associated with mutations in BRCA gene³. Because of its similarities histologically, UPSC may be a manifestation of a field error in carriers of BRCA1, which also comprises ovarian malignancy, fallopian tube malignancy, and primary peritoneal malignancies.

Case Presentation

Mrs. N, 70yrs old nulligravida, post menopausal 20 years back, came with the chief complaints of vague lower abdominal pain and discomfort since 1 month and post menopausal bleeding since 6 days. She has history of Diabetes Mellitus, Hypertension, Hypothyroid and Medical renal disease Grade I.

Her general and systemic examination were normal.

Per abdomen examination - Soft, Mild Suprapubic tenderness +, No guarding/ rigidity, No palpable mass, No organomegaly.

Per speculum – Minimal bleeding present

Per vaginal examination – Cervix - high up, pointing upwards, Uterus-bulky, 8-10 wks size, Fornices free.

Transvaginal scan - Uterus - 8.8x3.4 cms, Bulky, Endometrial thickness-32mm. Diffuse areas of echogenicity with two small anechoic areas (0.2x0.1cms) seen within the endometrial cavity.

Differential Diagnosis considered were, Endometrial Carcinoma, and Submucosal fibroid.

All preoperative Investigations were done and were normal.

Tumor markers were elevated (Ca 125- 53units/ml, LDH- 236unit/l)

Patient was taken up for examination under anesthesia and Endometrial biopsy taken

HPE Report - Suggestive of uterine papillary serous carcinoma.

MRI done - Suggestive of Endometrial mass probably Endometrial Carcinoma with pelvic lymph node involvement. (Fig 1)

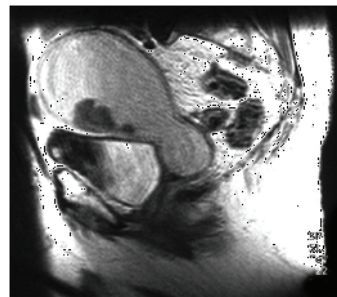


Fig 1 : MRI showing Uterine Papillary Serous Carcinoma Patient was taken up for Staging Laparotomy

Under General anaesthesia, Vertical paramedian incision made. Peritoneal washings obtained. Intra-operative findings-Uterus-10wks size, Bilateral ovaries atrophic, Pelvic and para-aortic lymph nodes enlarged, Sigmoid mesentery infiltration present. Proceeded with Total abdominal hysterectomy with bilateral salpingo - oophorectomy with pelvic and para-aortic lymph node dissection and resection of sigmoid mesentery with omental sampling was done and specimen sent for HPE. Intraperitoneal drain was placed.

2 units of Packed Red Blood Cell transfusion done intraoperatively. Postoperatively treated with antibiotics and analgesics. Post-op period was uneventful.

HPE Report - Papillary serous carcinoma of endometrium. Tumor involves >1/2 of myometrium. Cervical stroma not involved by tumor. Right pelvic, left pelvic, paraaortic lymph nodes and sigmoid colon are involved by tumor. Right ovary and left fallopian tube are involved by tumor.

Diagnosis - Uterine Papillary Serous Carcinoma - Stage III C2.

Patient advised for post operative chemotherapy and pelvic radiation.

Discussion

History²

In 1981 - Lauchlan & Hendrikson – First identified the condition

In 1983 - Bokhman – 1st proposed hypothesis of 2 distinctly different forms of endometrial carcinoma

Types^{4,5}

Type - I - Estrogen dependent (90%)
(adenocarcinoma–adenoacanthoma, adenosquamous, secretory, ciliated & villoglandular variants)

Type - II - Nonestrogen dependent (10%)
(Uterine papillary serous carcinoma & clear cell carcinoma)

Feature	Type - I	Type - II (UPSC)
Estrogen stimulation	Present	Absent
Growth	Slow	Rapid
Precursor lesion	Atypical hyperplasia	Endometrial glandular dysplasia
Age (initial diagnosis)	Pre / Perimenopausal	Postmenopausal
Built	Obese	Thin
Histology	Endometroid	Serous,clear cell
Histology Grade	High, Intermediate or low	High
Depth of invasion	Usually superficial	Often deep
Molecular Changes	Defects inDNA mismatch repair PTEN inactivation	P53 mutation HER-2/neugene amplification

Table 1 : Features of Type I and Type II Endometrial Carcinoma⁴

UPSC - Its Significance

- Distinct subtype of Endometrial carcinoma both clinically and pathologically
- Typically arises in postmenopausal women
- Endometrial hyperplasia is not a source of UPSC
- Not hormone dependent and very aggressive
- Seen in patients with endometrial atrophy
- Outcome is identical to that of high grade ovarian carcinoma in serous type

Incidence Of Endometrial Carcinoma⁶

4th most common cancer following Carcinoma Breast, Colorectal Carcinoma & Carcinoma Lung

Developed countries – 22/100,000 (41,000 new cases-USA)

Urban India – 5.8 / 100,000

Rural India – 0.8 / 100,000

Although UPSC is not so common than its endometroid cancer analogue, it explains for a disproportionately high cancer related deaths due to endometrial malignancy.

UPSC – 5-8% of endometrial cancer.

UPSC - 40% endometrial cancer related deaths.

Diagnosis

Usually present with postmenopausal bleeding, occasionally abdominal mass

Tissue diagnosis – Endometrial biopsy / Dilatation and Curettage.

Tumor marker - Ca-125

Ultrasound, Computed Tomography & Magnetic resonance Imaging - for diagnosis & to look for metastasis

Histology

Marked nuclear atypia (enlarged size with irregular nuclear membrane) is seen. There are nipple shaped structures (papillae) with fibrovascular cores, Psammoma bodies and Cilia.

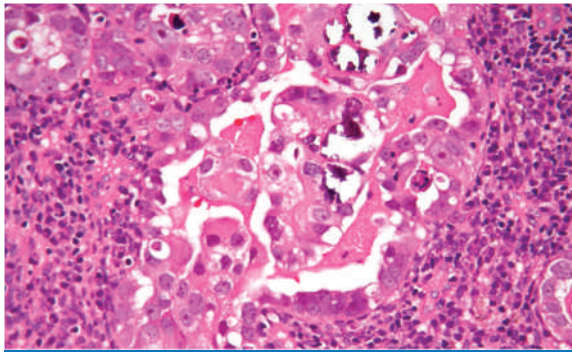


Fig 2 : Histology of Uterine papillary serous carcinoma

Staging Of UPSC : FIGO 7

Stage I A - Tumor is limited to less than half the myometrium

Stage I B - Tumor is limited to more than half the myometrium

Stage II - Cervical stromal invasion

Stage III A : Tumor invades serosa or adnexa

Stage III B : Vaginal or parametrial metastasis
 Stage III C 1 : Metastasis to pelvic lymph nodes
 Stage III C 2 : Metastasis to para aortic lymph nodes
 Stage IV A : Invasion of the bowel or bladder
 Stage IV B : Distant metastasis

Survival Rate⁷

Earlier Stage I & II : 35 - 50%

Stage III & IV : 0 - 15%

Recent Gynaecology Oncology Group (GOG) – 5 year survival rate

Stage I : 50 – 75%

Stage II : 50%

Stage III : 20%

Stage IV : 10%

Treatment^{6,7}

Surgical – Total abdominal hysterectomy with bilateral salpingo-oophorectomy with pelvic and para-aortic lymphadenectomy and omental sampling.

The tumor spreads quickly into myometrium and lymphatic system

If tumor spreads – cytoreduction followed by radiation therapy and/ or chemotherapy

Radiation – Shows no increase in survival rate

Chemotherapy – Beneficial- yet more data needed

Women with advanced stage UPSC are best treated with optimal cytoreduction of metastatic disease followed by adjuvant platinum based chemotherapy (carboplatin and paclitaxel or cisplatin and adriamycin). Careful long term surveillance following surgery is indicated due to its high recurrence rate. ³

Stage	Recommendation
Stage IA, grade I-II	Total abdominal hysterectomy with bilateral salpingo-oophorectomy, with lymph node sampling
Stage IA - grade III, Stage IB, Stage II	Total abdominal hysterectomy with bilateral salpingo-oophorectomy following which pelvic irradiation is given
Stage III A, grade I-II	Total abdominal hysterectomy with bilateral salpingo-oophorectomy following which pelvic irradiation is given
Stage IIIa, high grade, III B, C	Total abdominal hysterectomy with bilateral salpingo-oophorectomy following which chemotherapy and pelvic irradiation are given
Stage IV	Systemic treatment; chemotherapy and/or progestins are given

Table 2: Treatment Guidelines of Endometrial Malignancy⁸

Recent Advances

About 60% of UPSC's was found to have an overexpression of HER2/neu protein, as in breast cancer. Monoclonal antibody - Trastuzumab (Herceptin), has been tested with little success, in phase-II trial. ⁹

Conclusion

UPSC reveals atypical findings on MR imaging: low intensity on T2WI and rapid strong enhancement on dynamic MRI. If UPSC is preoperatively diagnosed in cytological examination, we should be careful in staging because this tumor shows atypical findings on MR imaging and often has dissemination and distant metastases. ¹⁰

87% of cases report Type I endometrial cancer (endometrioid subtype). 13 - 15% of cases reports Type II papillary serous type and clear cell type. Endometrioid subtype is hormone dependent, while a major molecular aberration p53 mutation is seen in type II cancers with serous type. Outcome and biology is identical to that of high grade ovarian malignancy in serous type. For solitary or isolated recurrences, surgery is a preferable option. Chemotherapy profits for patients with disseminated or metastatic disease. Hormonal therapy with medroxyprogesterone is a justifiable option for patients with type I endometrial malignancy with spread of the disease. Paclitaxel, Carboplatin, and adriamycin are the most effective drugs used in chemotherapy.

References

- 1) Hendrickson M, Ross J, Eifel P, Martinez A, Kempson R. Uterine papillary serous carcinoma: a highly malignant form of endometrial adenocarcinoma. *Am J Surg Pathol.* 1982 Mar;6(2):93-108.
- 2) Jemal A, Siegel R, Xu J, Ward E. Cancer Statistics, 2010. *CA Cancer J Clin.* 2010; 60(5): 277 - 300.
- 3) Kelly MG, O'malley DM, Hui P, McAlpine J, Yu H, Rutherford TJ et al. Improved survival in surgical stage I patients with uterine papillary serous carcinoma (UPSC) treated with adjuvant platinum based chemotherapy. *Gynecol Oncol* 98(3): 353-9.
- 4) Grundker C, Gunthert AR, Emons G. Hormonal heterogeneity of endometrial cancer. *Adv Exp Med Biol.* 2008:630:166-88.
- 5) Bokhman JV. Two pathogenetic types of endometrial carcinoma. *Gynecol Oncol.* 1983;15(1):10-7.
- 6) Fader AN, Boruta D, Olawaiye AB, Gehrig PA. Uterine papillary serous carcinoma: epidemiology, pathogenesis and management. *Curr Opin Obstet Gynecol.* 2010;22(1):21-2.
- 7) Chan JK, Loizzi V, Youssef M, Osann K, Rutgers J, Vasilev SA et al. Significance of comprehensive surgical staging in noninvasive papillary serous carcinoma of the endometrium. *Gynecol Oncol.* 2003; 90(1):181-5.
- 8) Colombo N, Preti E, Landoni F, Carinelli S, Colombo A, Marini C et al. Endometrial Cancer: ESMO Clinical Practice Guidelines. *Ann Oncol* 2013; 24 (Suppl 6): vi33-vi38.
- 9) Santhin AD, Bellone S, Roman JJ, McKenney JK, Pecorelli S. Trastuzumab treatment in patients with advanced or recurrent endometrial carcinoma overexpressing HER2/neu. *Int J Gynaecol Obstet.* 2008; 102(2): 128-31.
- 10) Park BK, Kim B, Park JM, Ryu JA, Kim MS, Bae DS et al. Differentiation of the various lesions causing an abnormality of the endometrial cavity using MR