

Case Report

Dental Implants with Simultaneous Guided Bone Regeneration

Dr.V.Anitha¹, Dr.V.Shivakumar², Dr.M.Shanmugam³, Dr.R.Saravanakumar⁴

¹Associate Professor, ²Professor and Head of the Department, ³Reader, ⁴Professor, Department of Periodontics, Chettinad Dental College and Research Institute (CDCRI), Kelambakkam, Tamil Nadu, India.



Dr.V.Anitha is presently working as an Associate Professor, in the department of Periodontics, in Chettinad Dental College and Research Institute, Kelambakkam. She has completed her under graduation in 1997 from R.V. Dental college, Bangalore. She has completed her post graduation in 2004 from Meenakshiammal Dental College (Dr. Tamil Nadu M.G.R. Medical University). She has got around 3 International publications and 15 National publications. She has received Dr. K.L. Baby award for the best scientific article from the Kerala state dental association.

Corresponding author - Dr.V.Anitha (anithasubiksha@gmail.com)

Abstract

Bone defects at mandibular alveolar crest level complicate the placement of dental implants in the ideal location. Surgical reconstruction using bone grafts allows implant fixation in an aesthetic and functional manner. We describe a patient with presence of Seibert class B ridge in relation to maxillary anteriors secondary to periodontal inflammatory processes. Reconstruction of the mandibular alveolar process was carried out using allograft (Bio-oss) simultaneously with placement of dental implants. One year post operatively considerable increase in the volume of bone was evident on CT scan in the augmented area. Good implant stability was achieved at 6 months and one year postoperatively following placement of the crown with no gingival deformation around the implants.

Key words: Dental Implants, Guided bone regeneration, Alveolar bone defects.

Chettinad Health City Medical Journal 2012; 1(3): 128 - 130

Introduction

Dental implants have become a predictable and successful long term treatment modality in periodontally compromised alveolar ridge. The placement of implants in a prosthetically driven position is clinically challenging. The certainty of implants depends on the quantity and quality of available bone. When the alveolar ridges lack sufficient bone volume, additional surgical procedures are required to augment the deficiencies¹. Advanced procedures such as Guided bone regeneration have provided a conducive environment for successful placement of implants. In Guided bone regeneration non osseous cells are inhibited and osteoblast derived from the periosteum and the bones are induced to form new bone. There are two approaches in Guided bone regeneration (GBR) - simultaneous and staged approach². In simultaneous approach fixture placement and GBR are performed simultaneously and is indicated only in narrow ridge defects. In staged approach GBR is used to increase the alveolar ridge before fixture placement. This article presents a case report of simultaneous approach of guided bone regeneration and implant placement in maxillary anteriors³

Case history

A female patient aged 26 years reported to the Department of Periodontology, Chettinad Dental College and Research Institute with a chief complaint of missing anterior teeth and need for replacement. The patient gives the history of extraction due to mobility of upper and lower anterior teeth one year back. On transgingival probing the presence of Seibert class

B ridge in relation to maxillary anteriors 12 was evident. The three dimensional software analysis and Computed Tomography revealed the presence of deficient bone volume in 12 regions. The treatment plan included the placement of two stage implants in upper anterior along with simultaneous guided bone regeneration in relation to 12.

The surgical procedure included placement of crestal incision extending from 13-23, followed by elevation of full thickness mucoperiosteal flap (Fig-1,2). The dimensions of the ridge was deficient measuring 13.5 mm in length and 4.1 mm in width in 12 region and in other maxillary incisor region measuring around 12 mm x 0.5 mm.(Fig-3,4). Three maxillary implants with the dimension of 11mm x3.3 mm was placed in 11, 21, 22 region and 10 mm x 3.3 mm dimension of implant placed in 12 region. The primary stability was good in relation to all implants but in the midlabial surface of 12 regions two threads were exposed due to deficient ridge. This defect was treated with simultaneous guided bone regeneration using alloplast (Bio-oss) in relation to 12 regions (Fig-5). Flaps were sutured with No 3-0 black silk and primary closure was achieved. Antibiotics and analgesics were prescribed. Patient was advised to clean the surgical area with cotton dipped in 0.2% chlorhexidine mouth wash twice a day. Patient was called after one week and suture removal was performed. Two weeks following suture removal maxillary removable partial denture was given. Six months post operatively the maxillary second stage surgery was performed. The implant head was exposed using a crestal incision and the healing cap was placed in the maxillary implants (Fig-6). 2 weeks post

operatively a well formed gingival cuff was evident. The implant analog was placed and the impression was taken with rubber base impression material. The implant analog was transferred to the impression and the working model was made and ceramic crown was prepared. The abutment was placed followed by cementation of ceramic crowns in the patient’s mouth (Fig-7). The patient was given proper supportive periodontal therapy and recalled every three months for one year to evaluate the periodontal status.

Post operatively a well formed gingival cuff was evident. The implant analog was placed and the impression was taken with rubber base impression material. The implant analog was transferred to the impression and the working model was made and ceramic crown was prepared. The abutment was placed followed by cementation of ceramic crowns in the patient’s mouth (Fig-7).

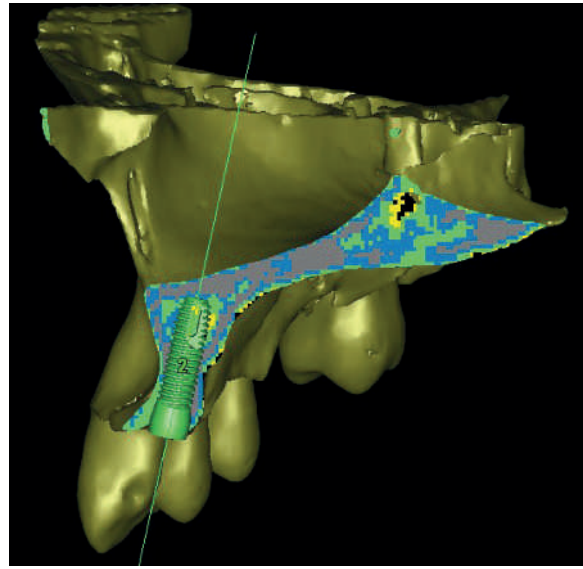


Fig 4: 3D lateral view of maxilla

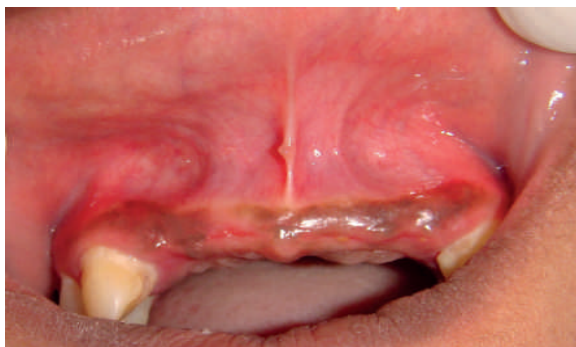

Fig 1: Preoperative view

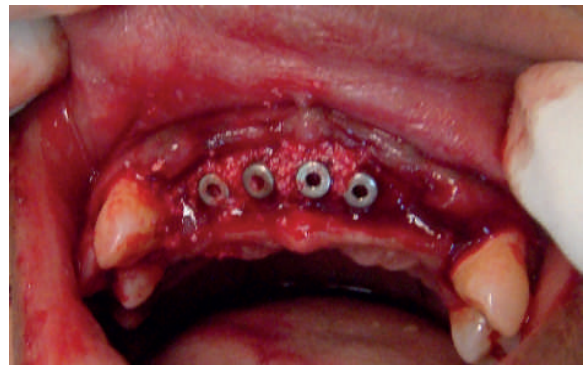

Fig 5: Dental implant placement with bone grafting (Bio-Oss)

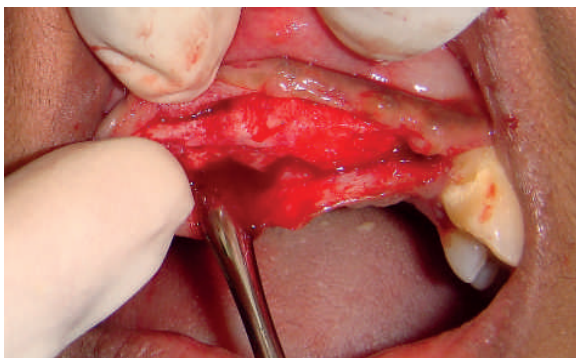


Fig 2: Elevation of Full thickness mucoperiosteal flap

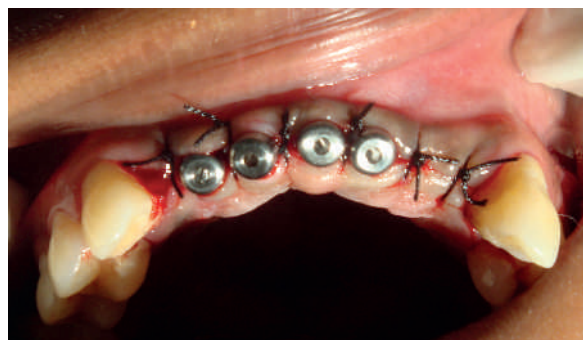

Fig 6: Placement of healing cap

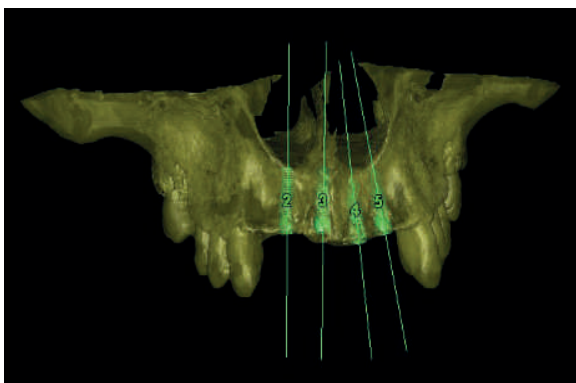


Fig 3: 3D facial view of maxilla

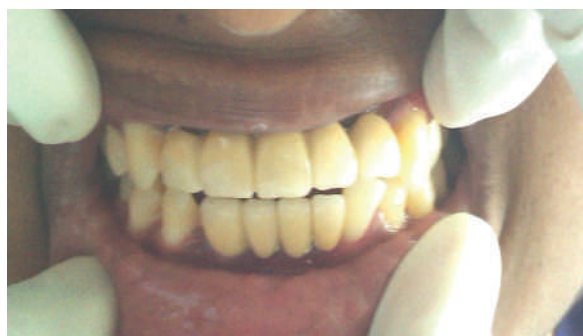

Fig 7: Postoperative with fixed prosthesis

The patient was given proper supportive periodontal therapy and reviewed every three months for one year to evaluate the periodontal status.

Discussion

Guided Bone Regeneration is a surgical procedure that utilizes barrier membranes to direct the growth of new bone and gingival tissue at sites having insufficient volumes or dimensions of bone. The present scenario focuses on the application of guided bone regeneration to defective alveolar ridges facilitating the placement of implants^{4, 5}.

Alveolar bone defects can be surgically corrected before or at the time of implant placement. The advantage of performing the combined graft implant procedure in a single step is reduction in the number of surgical intervention and graft stabilization procured by the implant. The disadvantages of the combined graft implant procedure are graft failure leading to implant failure and deficiency of Osseointegration in the coronal portion of the implant⁶.

In this present case report simultaneous GBR was performed in the maxillary right lateral region during implant placement achieving good primary implant fixation and graft stability^{7,8}. One year post operatively considerable increase in the volume of bone was evident on CT scan in the augmented area. Good implant stability was achieved at 6 months and one year postoperatively following placement of the crown with no gingival deformation around the implants. This is facilitated by maintenance of good oral hygiene.

The characteristics of regenerated bone are more dependent upon the bone quality of the receptor bed than on quality of the grafted bone, and in the case of simultaneous implant positioning; the achievement of increased percentage of bone-implant contact is dependent upon this same factor.

The outcome was implant survival described as presence of implant, implant success (according to the criteria in the respective study), absence of clinical implant mobility, absence of implant fracture, absence of progressive peri-implant crestal bone loss as assessed on radiographs without clinical signs of peri-implant infection, absence of peri-implant infection with suppuration. The survival rate of implants placed into sites with regenerated/augmented bone using barrier membranes varied between 79% and 100% with the majority of studies indicating more than 90% after at least one year of function.

The biological principle of GBR is highly predictable for ridge enlargement or defect regeneration under the prerequisite of a complication-free healing. The harmony of soft and hard tissue was achieved by implant placement with bone augmentation in aesthetically challenging situation^{9,10}. Immediate placement of implants with simultaneous ridge augmentation may be a treatment option with higher patient satisfaction compared with conventional delayed approach. Further evaluation is needed to

monitor hard and soft tissue changes on a long-term basis.

References

- 1) Ricardo Gapski, Hom-Lay Wang, Paulo Mascarenhas, Niklaus P Lang, and Critical review of immediate implant loading, *Clinical oral Implants Research*, 2003, volume 14, pages 515-527.
- 2) Christoph H. F. Hämmerle, Ronald E. Jung, Andreas Feloutzis, A systematic review of the survival of implants in bone sites augmented with barrier membranes (guided bone regeneration) in partially edentulous patients, *Journal of Clinical Periodontology*, 2002, Volume 29, pages 226-231.
- 3) L. G. Persson, I. Ericsson, T. Berglundh, J. Lindhe, Guided bone regeneration in the treatment of peri-implantitis, *Clinical oral implant research*, 1996, volume-7, pages 336-372.
- 4) D. Buser, U. Brägger, N. P. Lang, S. Nyman, Regeneration and enlargement of jaw bone using guided tissue regeneration, *Clinical Oral Implants Research* 1990, Volume 1, pages 22-32.
- 5) D. Lundgren, L. Sennerby, H. Falk, B. Friberg, The use of a new bioresorbable barrier for guided bone regeneration in connection with implant installation. *Clinical Oral Implants Research*, 1994, Volume 5, pages 177-184.
- 6) Paulino Castellon, Markus b, Blatz, Michael S. Block, Israel M. Finger, Bill Rogers. Immediate loading of dental implants in the edentulous mandible. *J Am Dent Association*, 1543-1549, Volume 135, page 011.
- 7) Jun-Beom Park, Restoration of the maxillary anterior tooth using immediate implantation with simultaneous ridge augmentation. *IJDR*, 2010, Volume: 21, Page: 454-456.
- 8) Péter Windisch, Dóra Szendrői-Kiss, Attila Horváth, Zsuzsanna Suba, István Gera, Anton Sculean. Reconstructive periodontal therapy with simultaneous ridge augmentation, *Clinical Oral Investigation* 2008 .volume 12 (3), page no 257-264.
- 9) Roberto cocchetto, Giampaolo vincenzi. Delayed and immediate loading of implants in the esthetic zone, *Practical proceed esthetic dentistry* 2007. Volume 22, page no 3.
- 10) Sompop Bencharit, Debra Schardt-Sacco, Michael B. Border, Colin P. Barbaro, Full Mouth Rehabilitation with Implant-Supported Prosthesis for Severe Periodontitis: A Case Report, *Open dentistry journal*, 2010, Vol-4, 165-171.