

Review Article

Autoimmune Hemolytic Anemia

Durga Krishnan*, Noorul Ameen S**, Aravind CS***, Balaji R***

*Professor, **Associate Professor, ***Senior Resident, Chettinad hospital and research institute, Chettinad Academy of Research & Education, Chennai, India.



Dr Durga did her undergraduation and postgraduation from Mahatma Gandhi Memorial Medical College, Indore. Her area of interest is Cardiology

Corresponding author - Durga Krishnan (drdurga79@gmail.com)

Chettinad Health City Medical Journal 2017; 6(2): 52 - 59

Abstract

Autoimmune hemolytic anemia (AIHA) is caused by autoantibodies that react with Red Blood Cells. It is an uncommon entity. Even being a well-recognized entity for so many years, there are lot of difficulties regarding its diagnosis and therapies used for treatment. There are different types of autoimmune hemolytic anemia like warm antibody hemolytic anemia, cold agglutinin disease/paroxysmal cold hemoglobinuria and mixed type. The warm antibodies react at temperatures $\geq 37^{\circ}\text{C}$ and cold agglutinin disease/ paroxysmal cold hemoglobinuria react at $< 37^{\circ}\text{C}$. Usually the hemolysis is extravascular. The positive direct antiglobulin (direct Coombs) test establishes the diagnosis and may suggest the cause. Treatment is usually cause dependent and includes corticosteroids, splenectomy, IV immune globulin, immunosuppressants and withdrawal of drugs.

Key Words: Autoimmune hemolytic anemia, AIHA, Autoantibodies, Warm Antibody, Cold Antibody, Mixed AIHA.

Introduction

Autoimmune hemolytic anemia (AIHA) is a group of disorders characterized by an impairment of the immune system which produces auto-antibodies (auto erythrocytes antibodies AEA), that act against one's own red blood cells considering it as foreign substance to the body. The main feature in immune related RBC injury is decreased RBC survival in-vivo along with confirmation of host antibodies that react with heterologous RBCs. AIHA can be primary or idiopathic and secondary. Secondary AIHA could be due to infections, autoimmune diseases, lymphoma or lympho-proliferative disorder and drugs¹. To establish these antibodies, the test used is direct antiglobulin test (DAT), also known by another name as Coombs test. A negative Coombs test does not exclude AIHA^{2,3}.

Etiopathogenesis

I. Warm-autoantibody (WA) type: autoantibody maximally active at body temperature (37°C)
A. Primary or idiopathic warm AIHA
B. Secondary warm AIHA
1. Associated with lymphoproliferative disorders (e.g., Hodgkin disease, CLL, lymphoma)
2. Associated with certain nonlymphoid neoplasms (e.g., ovarian tumors)
3. Associated with the rheumatic disorders, particularly SLE
4. Associated with certain chronic inflammatory diseases (e.g., ulcerative colitis)
5. Associated with ingestion of certain drugs (e.g., -methyldopa)
II. Cold-autoantibody (CA) type: autoantibody optimally active at temperatures $< 37^{\circ}\text{C}$
A. Mediated by cold agglutinin
1. Idiopathic (primary) chronic cold agglutinin disease
2. Secondary cold agglutinin hemolytic anemia

a. Postinfectious (e.g., Mycoplasma pneumoniae or infectious mononucleosis)
b. Associated with malignant B cell lymphoproliferative disorder
B. Mediated by cold hemolysins
1. Idiopathic (primary) paroxysmal cold hemoglobinuria (very rare)
2. Secondary
a. Donath-Landsteiner hemolytic anemia, usually associated with an acute viral syndrome in children (relatively uncommon)
b. Congenital or tertiary syphilis in adults (very rare)
III. Mixed cold and warm autoantibodies
A. Primary or idiopathic mixed AIHA
B. Secondary mixed AIHA
1. Associated with the rheumatic disorders, particularly SLE
IV. Drug-immune hemolytic anemia
A. Hapten or drug adsorption mechanism
B. Ternary (immune) complex mechanism
C. True autoantibody mechanism

Table 1 - Classification of Hemolytic Anemia as a Result of Immune Injury⁴

AIHA = Autoimmune hemolytic anemia; SLE = Systemic lupus erythematosus, CLL = Chronic Lymphocytic Leukemia

Warm antibodies

The destruction of red blood cells in hemolytic anemia is due to the presence of autoantibodies, mediated by immunoglobulins mainly IgG, IgM, or IgA which may depend upon on the complement. These auto-antibodies generally react at temperature of 37°C and cause warm AIHA⁵. The activation of complement continues till the emergence and establishment of membrane attack complex (MAC) which leads to hemolysis⁶. Very rarely these warm auto-antibodies can be IgM related but it is not detected in the serum; it

combines with the RBCs, activates the complement and separates from the membrane leaving only the complement⁶⁻⁹.

When the RBCs are coated with IgG along with or without complement (C3c, C3d), the phagocytosis takes place by Fc gamma receptor in the spleen, whereas if it is coated only with the complement (C3c, C3d) without IgG, it is eliminated by complement-receptor phagocytosis in the liver (extra vascular hemolysis)⁶. In primary AIHA the only aberrant auto-antibody is anti erythrocyte auto antibody and it is specific for single RBCs membrane that is small range of auto-reactivity. In secondary AIHA (due to lymphoma, CLL (chronic lymphocytic leukemia), or SLE) the auto antibody are usually formed due to latent defect in immune system. The auto-antibodies formed secondary to drug is usually reversible on withdrawal of the drug⁴.

Cold antibodies

IgM auto-antibodies (usually monoclonal) are pentameric antibodies which after fixing with complement causes intravascular hemolysis and to a small extent C3d mediated extra-vascular hemolysis. These antibodies react at low temperature with optimal effect at 4°C⁵⁻⁷.

The thermal range of IgM auto-antibodies is from 0°C- 34°C and those antibodies which react at temperature close to physiological temperature are the most harmful and cause severe form of AIHA^{6,7}. These auto-antibodies are usually confirmed by positive DAT. Sometimes DAT could be positive for both IgG and high titres of C3d which shows that patient is having mixed type AIHA. In few cases DAT is negative and the patients present with severe form of disease which is refractory to treatment and has worst outcome¹⁰⁻¹². These are usually IgM associated warm autoantibodies which can be tested by dual direct agglutination test (DDAT)¹³. At this juncture, it is worth mentioning Donath-Landsteiner autoantibody, which is a biphasic cold hemolysin, causing complement-mediated hemolysis and contributes to paroxysmal cold hemoglobinuria which is common in children and very rare in adults^{1,14}.

Epidemiology

Hemolytic anemia represents approximately 5% of all anemias. Acute AIHA is relatively uncommon disease, with an incidence of 1-3 cases/100,000 population per year¹⁵. The prevalence of Cold agglutinin disease is 14 per million population¹⁶. The incidence of mixed autoimmune hemolytic anemia (both warm and cold) is approximately 1 in 80,000; and the occurrence of cold agglutinin disease is 1 in 300,000^{16,17}. Warm AIHA although a rare disease, can affect any age from infancy to old age but mostly common over the age of 40 years with peak incidence at the age of 70 years⁴. Not much is known about cold agglutinin disease, few reports say that it is more common in male children and female adults^{2,17,18}.

Diagnosis

The diagnosis of AIHA is mainly made by clinical presentation, lab findings and immune hematological diagnosis.

Clinical features of warm antibody associated AIHA

The features of warm AIHA are similar to that of any other hemolytic anemia. Usually the first presentation is jaundice along with other signs of anemia. These patients usually have mild to moderate splenomegaly. Those who presents with acute AIHA have severe anemia developing in short duration along with other profound features of anemia including hepatosplenomegaly, hyperapnea, tachycardia and even heart failure^{2,19}. Whenever a patient presents with sudden onset anemia, jaundice and splenomegaly, suspect AIHA and search for the causes and mechanisms in such cases.

Clinical features of cold antibody AIHA

The patient with cold agglutinin AIHA (CA-AIHA) usually presents as chronic hemolytic anemia with or without jaundice. Some patients also complain of dark coloured urine due to hemoglobinuria which represents intravascular hemolysis. On exposure to cold, they develop acrocyanosis and veno-occlusive features of fingers, toes and tip of nose because of blockage of micro-circulation by lysed RBCs. Skin ulceration is uncommon. There could be additional features of other underlying diseases like respiratory involvement in mycoplasma pneumonia and splenomegaly in lymphoproliferative disorders²⁰⁻²². In paroxysmal cold hemoglobinuria, the patient develops features after exposure to cold.

Drug induced Immune Hemolytic Anemia

The presentation of drug induced AIHA is variable. Drugs whose auto reactivity depends upon hapten/drug adsorption (like penicillin) and autoimmunity (like methyl dopa); and present with mild to moderate hemolysis. Other drugs like cephalosporins or quinidine whose autoimmunity depends upon ternary complex mechanism present as sudden and severe hemolysis with hemoglobinuria. Sometimes patients may present with acute renal failure.

Laboratory findings

Severity of presentation of AIHA is variable. In warm AIHA, the compensated hemolytic anemia usually shows reticulocytosis. In some cases AIHA is associated with auto immune thrombocytopenia when it known as Evans syndrome. In CA-AIHA, the patient presents with mild to moderate anemia, the hematocrit is low but not less than 15%. There is sudden decrease in hematocrit in patients with paroxysmal cold hemoglobinuria during an attack. The presentation of drug induced hemolytic anemia is almost similar to Warm AIHA and the peripheral smear may reveal polychromasia, spherocytosis (unless proved otherwise it is taken as immune hemolytic anemia), RBCs fragments, nucleated RBCs and sometimes erythrophagocytosis by monocytes.

Next important is the presence of indirect hyper-bilirubinemia with only modest increase in total bilirubin and presence of urobilinogen. The level of haptoglobin is low and LDH level is usually increased, but if normal does not rule out hemolytic anemia. Fig 1 represents an algorithm for approach to AIHA.

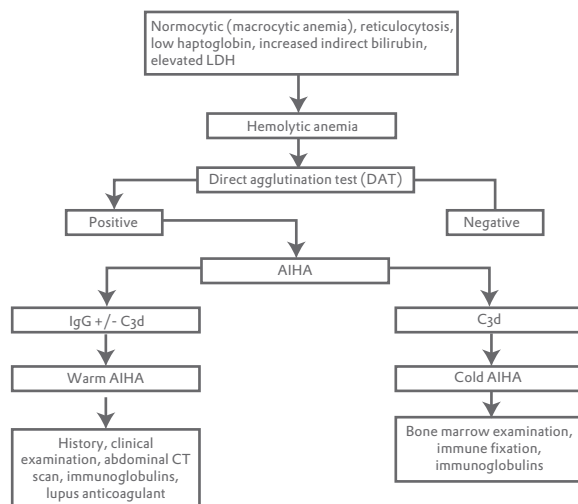


Fig 1 : Approach to Autoimmune hemolytic anemia (AIHA)

Immunohematological diagnostics

The diagnosis of AIHA and drug immune hemolytic anemia depends upon the detection of auto antibodies against RBCs. Direct and indirect antiglobulin test (Coomb's test) are done to demonstrate non-agglutinating red cell antibodies (indirect antiglobulin test, IAT) or sensitized red cells (direct antiglobulin test, DAT)²²⁻²⁴.

There are three possible designs for direct antiglobulin test for AIHA and drug induced hemolytic anemia: one is RBCs coated with only IgG, second is RBCs coated with IgG and complement components, and third is RBCs coated with complement components without detectable immunoglobulin.


Reaction pattern and type of injury based on IgG and complement is shown in table 2.

IgG alone	i) Warm antibody autoimmune hemolytic anemia ii) Drug-immune hemolytic anemia: hapten drug adsorption type or autoantibody type.
Complement	i) Warm antibody autoimmune hemolytic anemia with subthreshold IgG deposition. ii) Cold agglutinin disease. iii) Paroxysmal cold hemoglobinuria iv) Drug-immune hemolytic anemia: ternary complex type
Both IgG and Complement	i) Warm antibody autoimmune hemolytic anemia ii) Drug-immune hemolytic anemia: autoantibody type (rare)

Table 2 - Reaction pattern and type of injury based on IgG and complement

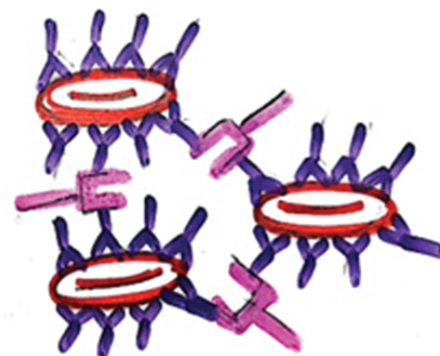
Direct antiglobulin test (DAT) tests the presence of in vivo antibodies. On the addition of polyspecific anti-human globulin reagent to RBCs, the RBCs agglutinate and the test is considered as positive^{27,28}. Sometimes when the suspicion of AIHA is strong and the DAT is negative, the test should be repeated with anti-IgA, anti-IgM, anti-IgG, anti-C3c and anti-C3d

separately, because the poly-specific anti human globulin contains only IgG, and C3d^{26,29}. If still the DAT remains negative, one should look for spherocytes in peripheral smear. When the DAT is positive with the polyspecific anti-human globulin reagent further testing with monospecific reagent is required to differentiate the type of auto-antibody whether it is IgM, IgG, IgA, C3c, or C3d (Fig 2). If antibody is negative and complement deposition is noticed, then one should think of CA-AIHA(IgM), WA-AIHA(IgM, IgA), or bithermic antibodies. Such situation warrants further laboratory investigations to ascertain the presence of either IgM or IgA⁵.



Patient erythrocyte coated with auto antibodies

serum directed to human IgG or complement C3c/d



agglutination patient erythrocytes

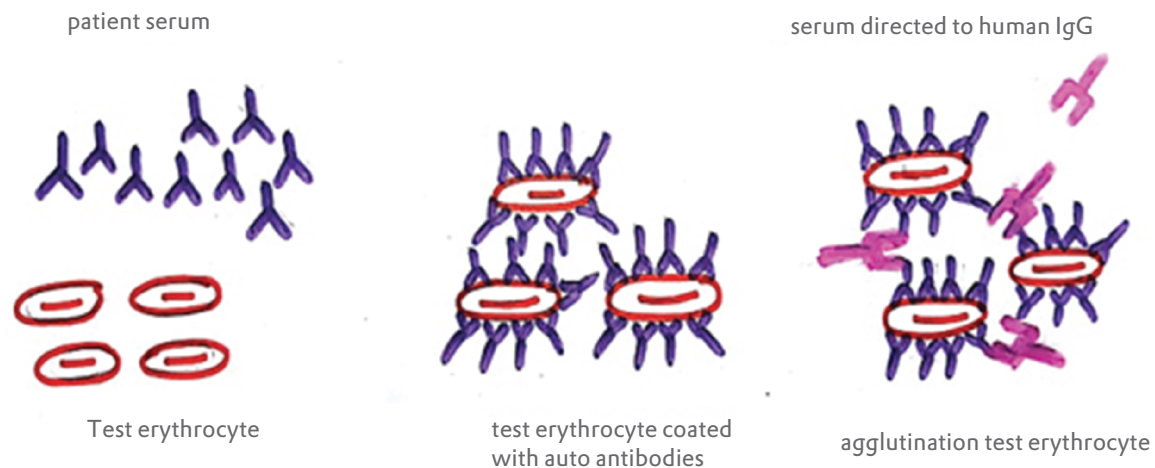
Fig 2 : Direct antiglobulin test (DAT)⁵

Indirect antiglobulin test (IAT) is used

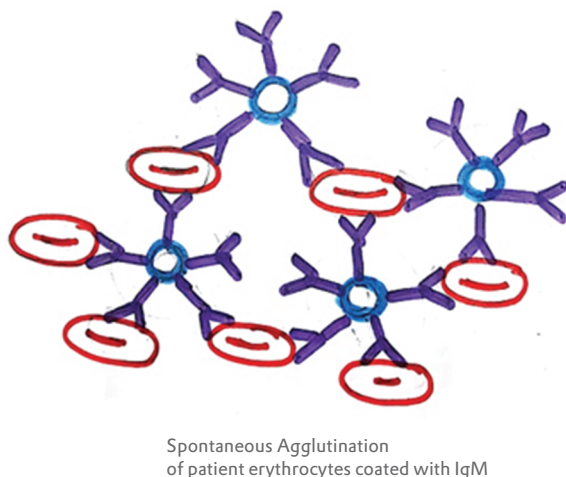
- 1) as a workup (intensive diagnostic study) of a transfusion reaction that has ABO incompatibility.
- 2) as a part of workup during a pregnancy that has Rh incompatibility.

In IAT (Fig 3), the patients serum consisting of auto or alloantibodies is mixed or incubated with labeled or non-labeled recipient blood or tested RBCs. In the second step, after washing the incubated sample to remove the excess immunoglobulin, the polyspecific anti-human globulin reagent directed against both IgG and C3d is added to the sample. If antibodies are present in the patients serum, it will get attached to RBCs and after addition of reagent, the RBCs will agglutinate indicating positive results. This is an in-vitro test and IgG are incomplete antibodies. If patient's serum contains IgM antibodies, there is agglutination soon after adding test RBCs and the result is positive (Fig 4). The differences between DAT and IAT are outlined in Table 3.

IAT

**Fig 3 : Indirect Antiglobulin test (IAT)**

SPONTANEOUS AGGLUTINATION

**Fig 4 : IAT in the presence of IgM antibody**

Direct	Indirect
Direct coombs test detects the presence of the antibodies attached to the surface of the red blood cells	Indirect coombs test detects the antibodies present in the serum which are not bound to the red blood cells.
This type is more commonly used	Indirect Coombs test are performed rarely
Direct coombs test is important to diagnose autoimmune hemolytic anemia.	Indirect coombs test is important for prenatal testing for pregnant women prior to blood transfusion
Direct coombs test can detect in vivo antigen-antibody interaction.	Indirect coombs test can detect in vitro antigen-antibody interactions.

Table 3 - Difference between Direct and Indirect Coombs Test³⁰**Treatment****General**

Blood transfusion- In general blood transfusion shall always be avoided as far as possible. If it is required and/or unavoidable, blood with least incompatibility should be selected and patients serum should be thoroughly checked for alloantibody which, if present, can lead to critical hemolytic transfusion reactions especially in patients with pregnancy and those who have received previous blood transfusion. If the patient is a non pregnant woman or in men without any prior history of transfusion, the chances of alloantibody are almost nil and they can go with transfusion after appropriate matching³¹. For other cases, from the point of patient safety one has to go ahead with phenotyping for other subclasses of Rh, Kell, Kidd, Duffy, Ss^{12,32-35}. In emergencies and resource limited situations, it is worth to consider the usage of transfusion set with filters.

Treatment of WA-AIHA**First line therapy****Corticosteroids**

The first line of treatment for WA-AIHA (primary) is corticosteroid (prednisolone). Algorithm for steroid treatment is shown in Fig 5. Approximately 20% of patient with WA-AIHA show complete remission with steroid and 10% show no or minimal response^{36,37}. All patients with steroid therapy should receive supplementation of vitamin D, bisphosphonates, calcium and folic acid. In those who are unresponsive to initial therapy, secondary causes like malignant tumor, ovarian teratoma(benign), inflammatory bowel disease(mainly ulcerative colitis) and warm IgM AIHA should be considered⁴⁰.

Second line therapy

Patients who require more than 15mg of steroid/day and/or refractory to initial steroid treatment are candidates for second line regimen^{2,38}. There are many options for second line treatment with somewhat proven efficacy. The two options are Splenectomy and Rituximab. Algorithm for treatment of steroid refractory WA-AIHA is given in Fig 6.

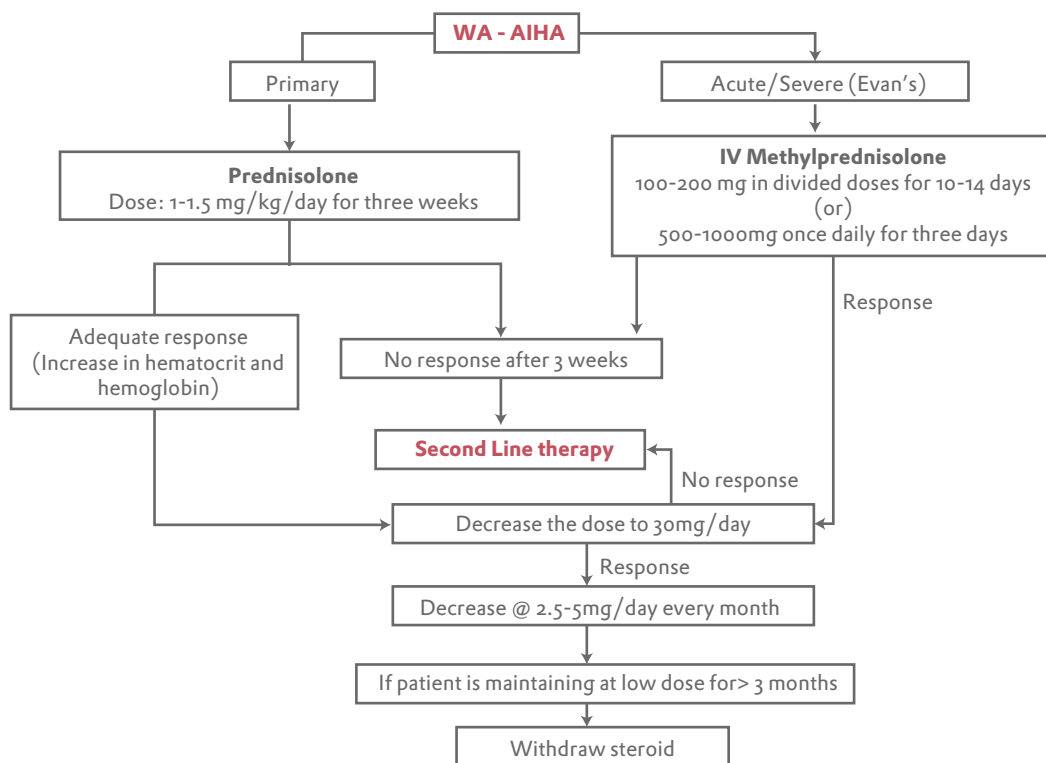


Fig 5 : Algorithm for treatment of WA-AIHA with corticosteroids³⁶⁻⁴⁰

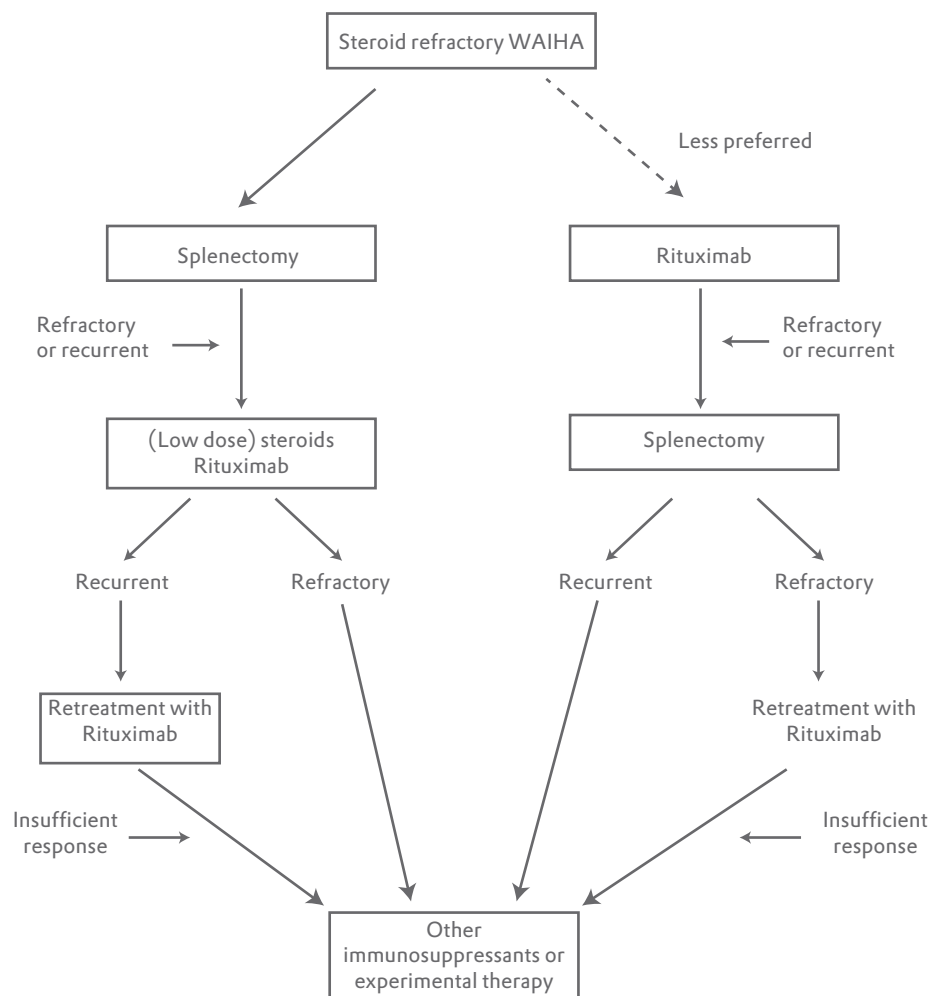


Fig 6 : Treatment of steroid refractory WA-AIHA

Splenectomy

Most accepted second line regimen is splenectomy, but available data on duration of complete or partial remission after splenectomy are less. The factors favouring this regimen are better initial response and interim effectiveness. Long remission was noticed among those patients who underwent splenectomy with or without steroid therapy^{41,42}. The remission is approximately 38-82% depending upon the percentage of secondary cases which are less responsive⁴³. With the laparoscopic approach there is lesser chance of perioperative complications like pulmonary embolism, abscess, bleeding etc. Patients should be vaccinated against encapsulated organisms such as *Pneumococcus*, *Meningococcus*, and *H.influenzae*. The mortality rate after splenectomy is more in children as compared to adults⁴⁴. The cure rate is approximately 20%.

Rituximab

It is a monoclonal anti-CD20 antibody which acts on B lymphocytes. It also shows good short term efficacy and is usually given in a dose of 375mg/m² in 4 doses for 4 weeks (1st day, 8th day, 15th day, 22th day). The actual response rate is not known. It is efficacious in both warm and cold AIHA with complete response rate of about 54-60%⁴⁵. If the patient is on steroid, they are advised to continue the same until the response with rituximab has started. It shows good response when used as a monotherapy or in combination with other drugs like steroid, immunosuppressant, interferon α , irrespective of previous treatment⁴⁶. It is highly responsive in patients with Evans syndrome. As such the drug is safe, and the long term side effects are progressive multifocal leukoencephalopathy. It is contraindicated in patients with untreated hepatitis B infection. Usually it is used in patients who refuse splenectomy or in whom the splenectomy is contraindicated.

Immunosuppressants

Azathioprine (dose 100 to 150mg/day) and Cyclophosphamide (100mg/day) can also be considered as second line therapy with response rate of 40-60%^{1,38}. Cyclosporine has also showed good response in patients with refractory warm AIHA⁴⁷. Only limited data is available for Mycophenolate mofetil which also showed good response in few studies.

Other modalities

Danazol, a synthetic anabolic steroid given with or after prednisolone is good for initial response, but less effective in refractory or relapse cases⁴⁸. Intravenous IG alone or in combination with corticosteroid is used mostly in children because of relatively less side effects. Plasmapheresis is used in warm AIHA in both children and adults in cases where steroid and transfusion are not able to control anemia on temporary basis.

Miscellaneous options

High dose Cyclophosphamide (50mg/kg/day for 4 days) along with GM-CSF have shown to be effective in highly refractory cases of WA-AIHA. Alemtuzumab an anti CD52 antibody and Ofatumumab, an anti CD20 antibody are also under trials.

Treatment of secondary AIHA

In SLE, the treatment is same as primary AIHA. For patients with CLL, prednisolone is the first choice (also in fludarabine associated AIHA). In active CLL, additional chemotherapeutic agents (Chlorambucil, R-CVP) and in refractory cases, rituximab and splenectomy are indicated. For Non Hodgkins Lymphoma, chemotherapy with or without rituximab may give a sustained response.

Treatment of CA-AIHA

Cold AIHA are usually secondary in nature and associated with lympho-proliferative disorders like IgM associated monoclonal gammopathy. The treatment is usually reserved for symptomatic cases. In asymptomatic cases, it may be moderately helpful to keep the extremities warm to avoid symptoms⁴⁹. Transfusion can be safely done in these patients by taking needed precautions such as keeping the patient warm. The use of steroids and splenectomy are not much useful and discouraged nowadays^{49,50}. The era for the treatment of CA-AIHA has changed after the introduction of rituximab. The drug is helpful in treatment because it is specifically directed against B-cell clone which is the culprit in many patients^{49,50}. The patients who are refractory to one or two courses of rituximab, a combination of rituximab and fludarabine (40mg/m² on 1st and 5th day) have shown high response rate and long duration of remission^{51,52}. Cold AIHA secondary to infection is usually self limited and treating the underlying cause is sufficient.

Paroxysmal cold hemoglobinuria (PCH) is generally known to occur with Donath Landsteiner antibody of IgG type, pointing against the P blood group system. Though PCH was previously associated with syphilis, it is now associated with other viral and bacterial infections. This is also a self limiting condition but may sometimes need treatment with steroids and transfusion.

Conclusion

AIHA is a well known hematological condition, whose clinical features, pathophysiology and diagnosis have been extensively described in literature. The discovery of Rituximab has remarkably improved treatment outcomes of AIHA.

References

- 1) Petz LD, Garratty G. The serologic investigation of autoimmune hemolytic anemia. In: Petz LD, Garratty G (Eds). *Immune hemolytic anemias*. 2nd ed. Philadelphia: Churchill Livingstone; 2004; 201-30.
- 2) Gehrs BC, Friedberg RC. Autoimmune hemolytic anemia. *Am J Hematol*. 2002; 69(4):258-71.
- 3) Packman CH, Leddy JP. Drug-related immune hemolytic anemia. In: Beutler E, Lichtman MA, Coller BS, Kipps TJ (Eds). *William's hematology*. 5th ed. New York: McGraw-Hill; 1995:691-704.

- 4) Engelfriet CP, Overbeeke MA, von dem Borne AE. Autoimmune hemolytic anemia. *Semin Hematol.* 1992;29(1):3-12.
- 5) Zeerleder S. Autoimmune haemolytic anaemia - a practical guide to cope with a diagnostic and therapeutic challenge. *Neth J Med.* 2011; 69(4):177-84.
- 6) Arndt PA, Leger RM, Garratty G. Serologic findings in autoimmune hemolytic anemia associated with immunoglobulin M warm autoantibodies. *Transfusion.* 2009;49(2):235-42.
- 7) Packman CH. Hemolytic anemia due to warm autoantibodies. *Blood Rev.* 2008;22(1):17-31.
- 8) Dacie J. Auto-immune haemolytic anaemia [AIHA]: pathogenesis. In: Dacie J (Edr): *The Haemolytic Anaemias*. Vol. 3. London, Churchill Livingstone, 1992: 392-451.
- 9) Kurlander RJ, Rosse WF, Logue GL. Quantitative influence of antibody and complement coating of red cells on monocyte-mediated cell lysis. *J Clin Invest.* 1978;61(5):1309-19.
- 10) Barcellini W, Fattizzo B, Zaninoni A, Radice T, Nichele I, Di Bona E, et al. Clinical heterogeneity and predictors of outcome in primary autoimmune hemolytic anemia: a GIMEMA study of 308 patients. *Blood.* 2014;124(19):2930-6.
- 11) Fattizzo B, Zaninoni A, Nesa F, Sciumbata VM, Zanella A, Cortelezzi A et al. Lessons from very severe, refractory and fatal primary autoimmune hemolytic anemias. *Am J Hematol.* 2015;90(8):E149-51.
- 12) Arndt PA, Leger RM, Garratty G. Serologic findings in autoimmune hemolytic anemia associated with immunoglobulin M warm autoantibodies. *Transfusion.* 2009;49(2):235-42.
- 13) Bartolmas T, Salama A. A dual antiglobulin test for the detection of weak or nonagglutinating immunoglobulin M warm autoantibodies. *Transfusion.* 2010;50(5):1131-4.
- 14) Berentsen S. How I manage cold agglutinin disease. *Br J Haematol.* 2011;153(3):309-17.
- 15) Gehrs BC, Friedberg RC. Autoimmune hemolytic anemia. *Am J Hematol.* 2002; 69(4):258-71.
- 16) Berentsen S, Bo K, Shammash F, Myking A, Ulvestad D. Chronic cold agglutinin disease of the 'idiopathic' type is a premalignant or low-grade malignant lymphoproliferative disease. *APMIS.* 1997;105(5):354-62.
- 17) Dacie J. *The auto-immune haemolytic anaemias. The Haemolytic Anaemias.* 3rd ed. Edinburgh, United Kingdom: Churchill Livingstone; 1992. Vol 3.: 210-362.
- 18) Sokol RJ, Booker DJ, Stamps R. Erythropoiesis: Paroxysmal Cold Haemoglobinuria: A Clinico-Pathological Study of Patients with a Positive Donath-Landsteiner Test. *Hematology.* 1999. 4 (2):137-64.
- 19) Packman CH, Leddy JP. Acquired hemolytic anemia due to warm-reacting autoantibodies In: Williams WJ, Beutler E, Erslev AJ, Lichtman MA, (Eds). *Hematology* New York: McGraw-Hill, Inc.1990. 666-75.
- 20) Swiecicki PL, Hegerova LT, Gertz MA. Cold agglutinin disease. *Blood.* 2013;122 (7):1114-21.
- 21) Prabhu R, Bhaskaran R, Shenoy V, G R, Sidharthan N. Clinical characteristics and treatment outcomes of primary autoimmune hemolytic anemia: a single center study from South India. *Blood Res.* 2016;51(2):88-94.
- 22) Berentsen S, Randen U, Tjnnfjord GE. Cold agglutinin-mediated autoimmune hemolytic anemia. *Hematol Oncol Clin North Am.* 2015;29 (3):455-71.
- 23) Darrell J. Triulzi, M.D. Indirect and Direct Antiglobulin (Coombs) Testing and the Crossmatch. *Transfusion medicine Updates* October 2000. <http://www.itxm.org/tmu/tmu2000/tmu10-2000.htm> (accessed on 08/10/2013)
- 24) Coombs RR, Mourant AE, Race RR. A new test for the detection of weak and incomplete Rh agglutinins. *Br J Exp Pathol.* 1945. 26:255-66.
- 25) Silberstein LE, Cunningham MJ. Autoimmune hemolytic anemias. In: Hillyer CD, Silberstein LE, Ness PM, Anderson KC, Roback JD (Eds). *Blood Banking and Transfusion Medicine: Basic Principles and Practice.* 2nd Edition. Philadelphia: Churchill Livingstone; 2007. 557-70.
- 26) Roback JD, Combs MR, Grossman BJ, Hillyer CD. *AABB Technical Manual.* 16th ed. Bethesda: AABB; 2008.
- 27) Segel GB, Lichtman MA. Direct antiglobulin ("Coombs") test-negative autoimmune hemolytic anemia: a review. *Blood Cells Mol Dis.* 2014;52(4):152-60.
- 28) Roback JD, Barclay S, Hillyer CD. An automatable format for accurate immunohematology testing by flow cytometry. *Transfusion* 2003;43(7):918-27.

- 29) Chaplin H Jr. Clinical usefulness of specific antiglobulin reagents in autoimmune hemolytic anemias. *Prog Hematol* 1973;8:25-49.
- 30) Bass GF, Tuscano ET, Tuscano JM. Diagnosis and classification of autoimmune hemolytic anemia. *Autoimmun Rev* 2014;13(4-5):560-4
- 31) Schonewille H, de Vries RR, Brand A. Alloimmune response after additional red blood cell antigen challenge in immunized hematocytology patients. *Transfusion*. 2009;49(3):453-7.
- 32) Go RS, Winters JL, Kay NE. How I treat autoimmune hemolytic anemia. *Blood* 2017;129(22):2971-9.
- 33) Valent P, Lechner K. Diagnosis and treatment of autoimmune haemolytic anaemias in adults: a clinical review. *Wien Klin Wochenschr*. 2008;120(5-6):136-51
- 34) Eyster ME, Jenkins DE Jr. Erythrocyte coating substances in patients with positive direct antiglobulin reactions: Correlation of G globulin and complement coating with underlying diseases, overt hemolysis and response to therapy. *Am J Med* 1969;46(3):360-71.
- 35) Shirey RS¹, Boyd JS, Parwani AV, Tanz WS, Ness PM, King KE. Prophylactic antigen matched donor blood for patients with warm autoantibodies: An algorithm for transfusion management. *Transfusion* 2002;42(11):1435-41.
- 36) Naithani R, Agrawal N, Mahapatra M, Kumar R, Pati HP, Choudhry VP. Autoimmune hemolytic anemia in children. *Pediatr Hematol Oncol*. 2007;24(4):309-15
- 37) Gupta V, Shukla J, Bhatia BD. Autoimmune Hemolytic Anemia. *Ind J Ped*. 2008;75(5):451-4
- 38) Lechner K, Jager U. How I treat autoimmune hemolytic anemias in adults. *Blood*. 2010;116(11):1831-8
- 39) Dussadee K, Taka O, Thedsawad A, Wanachawanawin W. Incidence and risk factors of relapses in idiopathic autoimmune hemolytic anemia. *J Med Assoc Thai*. 2010;93(Suppl 1):S165-S170
- 40) Alberto Z, Wilma B. Treatment of autoimmune hemolytic anemias. *Haematologica*. 2014;99(10): 1547-54.
- 41) Serrano J. Autoimmune hemolytic anemia. Review of 200 cases studied in a period of 20 years (1970-1989). *Sangre (Barc)*.1992;37(4):265-74.
- 42) Coon WW. Splenectomy in the treatment of hemolytic anemia. *Arch Surg*.1985;120(5):625-8.
- 43) Akpek G, McAneny D, Weintraub L. Comparative response to splenectomy in Coombs-positive auto-immune hemolytic anemia with or without associated disease. *Am J Hematol*. 1999;61(2):98-102.
- 44) Bisharat N, Omari H, Lavi I, Raz R. Risk of infection and death among post-splenectomy patients. *J Infect*. 2001;43(3):182-6.
- 45) Barcellini W, Zanella A. Rituximab therapy for autoimmune haematological diseases. *Eur J Intern Med*. 2011;22(3):220-9.
- 46) Peñalver FJ, Alvarez-Larrán A, Díez-Martin JL, Gallur L, Jarque I, Caballero D, et al. Rituximab is an effective and safe therapeutic alternative in adults with refractory and severe autoimmune hemolytic anemia. *Ann Hematol*. 2010(11);89:1073-80.
- 47) Barros MM, Blajchman MA, Bordin JO. Warm autoimmune hemolytic anemia: recent progress in understanding the immunobiology and the treatment. *Transf Med Rev*. 2010;24(3):195-210.
- 48) Ahn YS. Efficacy of danazol in hematologic disorders. *Acta Haematol* 1990;84(3):122-9.
- 49) Berentsen S, Tjønnfjord GE. Diagnosis and treatment of cold agglutinin mediated autoimmune hemolytic anemia. *Blood Reviews*. 2012;26(3):107-15.
- 50) Schreiber AD, Herskovitz BS, Goldwein M. Low-titer cold-hemagglutinin disease. Mechanism of hemolysis and response to corticosteroids. *N Engl J Med*. 1977;296(26):1490-4.
- 51) Swiecicki PL, Hegerova LT, Gertz MA. Cold agglutinin disease. *Blood*. 2013;122(7):1114-21.
- 52) Berentsen S, Randen U, Vagan AM, Hjorth-Hansen H, Vik A, Dalgaard J, et al. High response rate and durable remissions following fludarabine and rituximab combination therapy for chronic cold agglutinin disease. *Blood*. 2010;116(17):3180-4.