

# Case Report

## Congenital Diaphragmatic Hernia (Bochdalek Hernia) in an Adult

Dr.R.Anantharamkrishnan\*, Dr.K.Senthil Kumar\*\*, Dr.R.Karunanithi\*\*\*

\*Associate Professor, \*\*Assistant Professor, \*\*\*Professor, Department of Surgery, Chettinad Hospital and Research Institute, Kelambakkam, Tamil Nadu, India.



Dr.R.Anantharamkrishnan M.S., Dip in Lap., FMAS, is Associate Professor in the Department of Surgery. He did his M.B.B.S in Madras Medical College(1991 batch) and postgraduation in Kilpauk Medical College (2002 batch). He has done fellowship in minimal access surgery. He joined Chettinad Hospital and Research Institute in 2005. He has attended many national conferences and presented interesting clinical cases and case studies in surgery.

Corresponding author - Dr. R.Anantharamkrishnan (rrasm2003@gmail.com)

Chettinad Health City Medical Journal 2012; 1(2): 70 - 72

### Abstract

Bochdalek hernia, a congenital posterolateral hernia of the diaphragm, usually manifests in the neonatal period and occasionally in childhood. Symptomatic Bochdalek hernia is uncommon in adults. Patients are usually investigated and treated for other diseases, therefore diagnosis is purely incidental. Here we report a patient who presented with features of chronic respiratory distress, who on investigation was found to have diaphragmatic hernia which was later operated.

**Key Words:** Congenital diaphragmatic hernia, Bochdalek hernia, plication of diaphragm, mesh reinforcement.

### Introduction

Lazarus Riverius first described congenital diaphragmatic hernia (CDH) in 1690, which was found incidentally in a 24 year old man at post-mortem<sup>1</sup>. CDH occurs 1 in 2000-3000 live births and accounts for 8% of all major congenital anomalies. CDH generally presents in the first few hours of life. Traumatic hernia can present in any age group. CDH presenting late in adolescence and adult life is a very rare entity. CDH are well recognized defects in the diaphragm through which herniation of abdominal contents occur, whereas eventration of diaphragm is abnormally elevated portion of diaphragm (one or both) from paralysis or atrophy of muscle fibres. The continuity of the fibres of diaphragm and attachments with costal margins are maintained in eventration.

### Case Report

A 25 year old male patient was admitted in the medicine ward with complaints of breathing difficulty on and off for the past one and half years. The patient was examined and investigated for cardiac and respiratory disease, and a diagnosis of eventration of diaphragm was made and was transferred to the surgery department. On receiving the patient his vitals were stable with a pulse rate of 84/min, blood pressure of 130/80 mmHg, no pallor, no cyanosis. His apex beat was slightly shifted towards midline. Air entry was good on both sides. His bowel sounds were heard even in the thoracic region in the region of left fifth space onwards.

Investigations showed a normal haemogram. Chest X-ray revealed an elevated left hemidiaphragm with mediastinal shift to the right side. Ultrasound abdomen was normal. His ejection fraction was 58% with trivial mitral regurgitation secondary to mitral valve prolapse on Echocardiogram. Barium enema (fig 2) showed a left hemidiaphragm elevation and the left part of the transverse colon appeared to ascend high up in the left hemithorax. CT scan of chest (fig 1) confirmed the upward displacement of bowel loops and the bowel loops were seen till the level of mid chest on the left side, with deviation of heart to right.

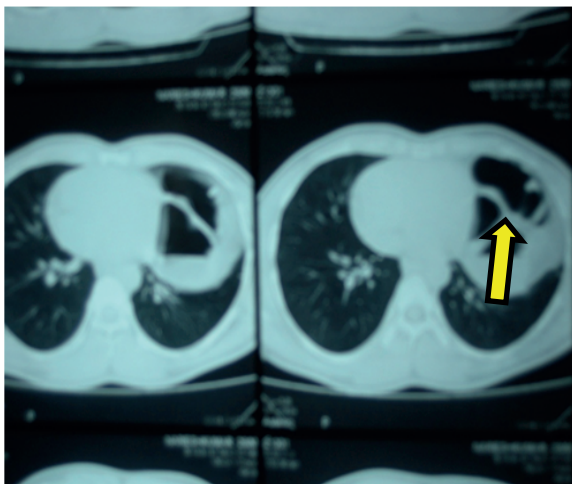
A diagnosis of left eventration of diaphragm was made. It was decided to plicate the diaphragm on the left side. The patient was taken up for surgery and the abdomen was opened by left subcostal incision. The diaphragm was highly placed and the left part of transverse colon was pulled up with the fundus of stomach and both appeared to be adherent to the diaphragm. Further dissection revealed a small defect of size 3 cms x 3 cms in the region of foramen of Bochdalek with a well formed sac with greater omentum as content herniating through the defect. Fundus of stomach and transverse colon were only adhered to the neck of the sac. The same were brought down. Omentum was reduced and the sac excised

(fig 3). Intercoastal drainage tube was introduced. The rent was closed with 1-0 prolene in two runs (fig 4). Postoperative period was uneventful and the patient slowly recovered from breathing difficulty and achieved complete relief of symptoms. The chest tube was removed when lung expansion was complete (fig 5).

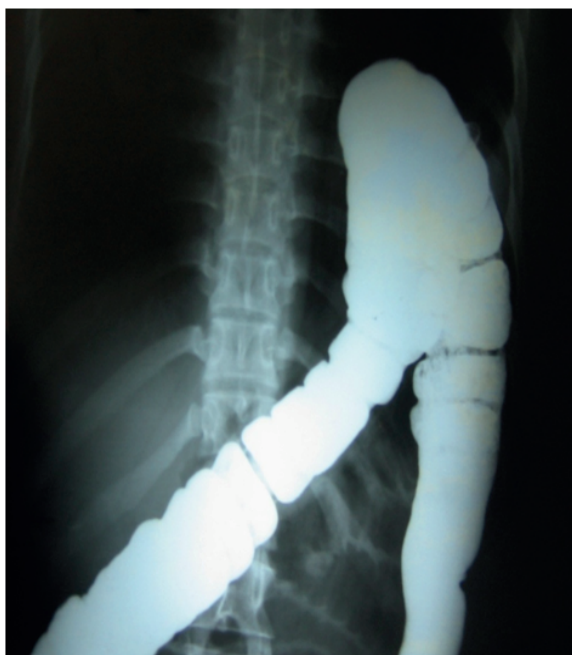## Discussion

The Bochdalek hernia is the most common type of CDH, accounting for more than 95% of cases<sup>2</sup>. The majority cases (80-85%) occur in left side of diaphragm<sup>3,4</sup>. Other types include Morgagni's hernia, eventration and central tendon defects. CDH has a mortality of 40-62%<sup>5</sup>, outcomes being more favourable in absence of other anomalies.

Bochdalek's hernia most commonly manifests during first few weeks of life. Diagnosis beyond 8 weeks of life represent 5-25% of cases.<sup>6</sup> In adults most hernias are likely to be asymptomatic and thus finding is incidental. The symptoms are typically vague and patients are evaluated for cardiac, respiratory or gastrointestinal diseases.<sup>3,6</sup>

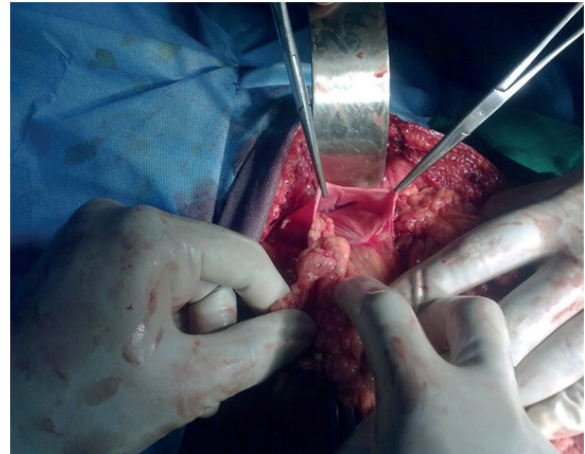


**Fig 1.** CT image showing bowel loops in the region of mid chest level on the left side

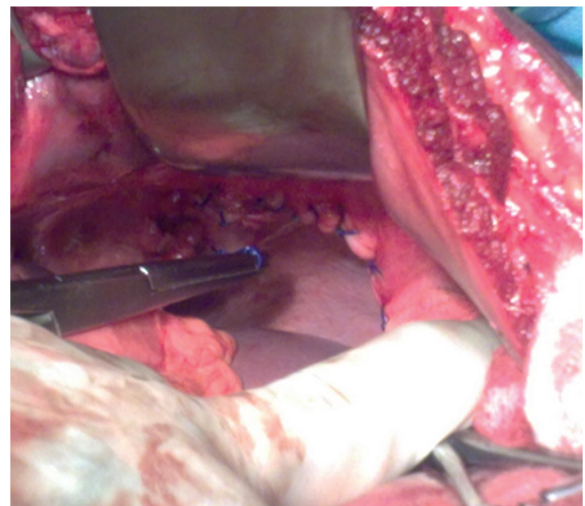


**Fig 2.** Barium enema showing transverse colon placed high in left hemithorax

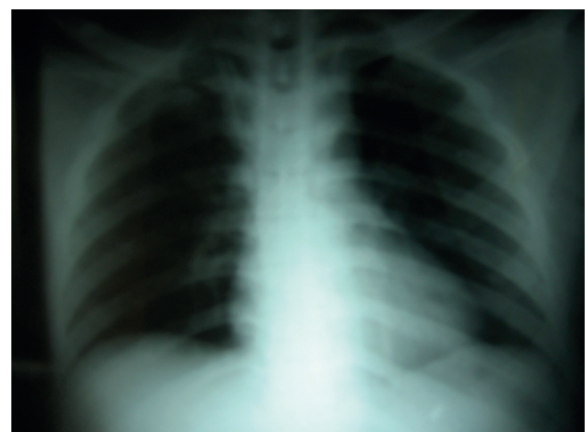
Treatment for eventration of diaphragm if symptomatic is surgical, just plication of the diaphragm without either incision of the membrane or excision of the pathologically altered segment. Patch reinforcement of a very thin membrane may be necessary.



**Fig 3.** Contents being reduced from the hernia sac



**Fig4.** Defect repaired using prolene sutures (non absorbable)



**Fig 5.** Postoperative chest X-ray showing adequate lung expansion

Treatment for diaphragmatic hernia is essentially surgical - exploratory laparotomy, reducing contents after checking viability, closing the defect primarily with non-absorbable suture material<sup>10,11</sup>. A synthetic mesh or Teflon patch may be used to reinforce the repair<sup>8</sup>. Laparoscopic repair and thoracoscopic repair has also been described in the literature<sup>9</sup>. In cases presenting early in infancy, children have also been stabilized before surgery using high frequency oscillatory ventilation followed by definite surgical correction<sup>7</sup>. In our patient we did a primary closure of the defect. Patient follow up for 2 years showed no recurrence of symptoms nor the hernia.

The occurrence of CDH in adults is rare and misleading even to experienced clinicians, as patients present with symptoms mimicking other diseases. Hence high index of clinical suspicion is required for prompt diagnosis and treatment in order to avoid complications such as strangulation or bowel perforation.

## References:

- 1) Ravitch MM .Congenital diaphragmatic hernia .In: Nyhus.In.Hernia.London: Pitman medical Publishing,London;1962.p.527-545.
- 2) Salacin S,Alper B,Cekin N,Gulmen MK.Bochdalek hernia in adulthood:a review and autopsy case report.J Forensic science. 1994;39:1112-1116
- 3) Fine R,Borrero E,Stone A.Bochdalek hernia in adulthood. N Y State Med Journal .1987; 87:516-518
- 4) Nitecki S, Bar –Maor JA. Late presentation of Bochdalek haernia:our experience and review of literature. Isr J Med Sci .1992;28:711-714
- 5) <http://emedicine/medscape.com/article/978118-overview>.
- 6) Hines GL,Romero C.Congenital diaphragmatic hernia in adult.Int Surg .1983;68:349-351.
- 7) Migliazza L, Bellan C, Alberti D, Auriemma A, Burgio G, Locatelli G, Colombo A . "Retrospective study of 111 cases of congenital diaphragmatic hernia treated with early high-frequency oscillatory ventilation and presurgical stabilization". J Pediatr Surg.2007;42(9):1526-32.
- 8) Logan JW, Rice HE, Goldberg RN, Cotten CM . "Congenital diaphragmatic hernia: a systematic review and summary of best-evidence practice strategies". Journal of perinatology : official journal of the California Perinatal Association. 2007; 27 (9): 535-49
- 9) Becmeur F, Talon I, Schaarschmidt K, et al. "Thoracoscopic diaphragmatic eventration repair in children: about 10 cases". J. Pediatr. Surg.2005; 40 (11): 1712-5.
- 10) Torfs CP, Curry CJ, Bateson TF, Honoré LH . "A population-based study of congenital diaphragmatic hernia". Teratology.1992; 46 (6): 555-65.
- 11) Gaxiola A, Varon J, Valladolid G "Congenital diaphragmatic hernia: an overview of the etiology and current management". Acta Paediatrica .2009;98(4): 621-627.

## Success Is in Your Hormones

Every dieter knows that it is relatively easy to lose weight but to keep it that way is far more difficult. While some succeed, most don't. Is there some way to predict who will and who won't? Ana Crujeiras Martinez, an obesity researcher at the University Hospital of Santiago de Compostela, feels there is. She took a close look at the ratio of two hormones that tell the body about satiety and hunger: leptin and ghrelin. In the study, Martinez evaluated 88 overweight or obese men and women with an average age of 35. The leptin/ghrelin ratio was measured before the start of an eight week dietary regimen and the subjects were followed up for another six months to see who regained the weight. She found that those who regained the weight had leptin/ghrelin ratio that was two times higher than those who did not. She presented the findings on 24/06/12 at the Endocrine Society's annual meeting in Houston.

[<http://news.health.com/2012/06/26/hormone-ratio-may-show-which-dieters-will-keep-weight-off/#more-57154>]

- Dr. K. Ramesh Rao