

# Review Article

## Endovascular Treatment of Intracranial Aneurysms

Srinivasan Paramasivam

Assistant Professor, Neurosurgery, Mount Sinai Hospital and Ichan school of Medicine, New York.



Dr. Srinivasan Paramasivam is a Neuroendovascular surgeon and Assistant professor of Neurosurgery at Mount Sinai Hospital and Ichan school of Medicine in New York. He is a Neurosurgeon trained in Institute of Neurology, Madras Medical College, Chennai. He then had his vascular neurosurgery and Interventional neuroradiology training at University of Zurich, Switzerland and then fellowship in Neuroendovascular surgery at St. Luke's Roosevelt hospital, an affiliate of Columbia University College of surgeons and physicians in New York. Since the completion of training he has been practicing neuroendovascular surgery in an academic setting and has recently joined Mount Sinai Hospital and Ichan School of Medicine. He has authored various peer-reviewed publications, book chapters and has been a reviewer for prominent neuroscience journals. He is involved in clinical, laboratory research and multicenter clinical trials.

Corresponding author - Srinivasan Paramasivam ([srinivasan.paramasivam@mountsinai.org](mailto:srinivasan.paramasivam@mountsinai.org))

Chettinad Health City Medical Journal 2014; 3(2): 46 - 55

### Introduction

Aneurysms of the cranial vessels are more prevalent (3% - 4%)<sup>1</sup> than it was thought before (1% -2%)<sup>2,3</sup>. They are mostly asymptomatic until they rupture<sup>4</sup> and unruptured aneurysms are increasingly detected in clinical practice as use of CT and MRI is becoming more common. The risk of aneurysm rupture is about 1% (0.05%-2%) per year and may vary with location, size, and shape<sup>5</sup>. The aneurysm rupture account for about 80-85% of non-traumatic subarachnoid hemorrhages<sup>6</sup> and can also cause intraparenchymal and intraventricular hemorrhage. Most aneurysms in both ruptured and unruptured setting are managed by endovascular means. We review here the current role of endovascular management of intracranial aneurysms.

### Evolution

Craniotomy for clip ligation was first successfully performed by Walter Dandy in 1937<sup>7</sup> and has been the treatment of choice for intracranial aneurysms since then. Following in the footsteps of the pioneering work of Serbinenko in Russia in the mid-1970s on management of vascular malformations of cranium using Balloon catheterization<sup>8</sup>, Higashida et al, attempted to treat posterior circulation aneurysms with detachable balloons by placing the balloon within the aneurysm and filling it with polymer intended to solidify over 40-60 minutes to provide a permanent solid filling of the aneurysm<sup>9</sup>. However, high rate of complications eventually led to this procedure being abandoned, but this experience demonstrated the feasibility of the endovascular route in the treatment of intracranial aneurysms<sup>10</sup>. The search for a more suitable material to fill an aneurysmal sac eventually led to the development of the detachable coil by Guglielmi et al, in 1990<sup>11-13</sup>. Though the initial coils were relatively stiff, and their intra-aneurysmal deployment was poorly controlled it led to the breakthrough that revolutionized the field and provided a real endovascular alternative to surgical clipping. The original Guglielmi detachable coil consisted of a stainless steel delivery wire attached to a soft, radiopaque platinum coil that was delivered into the aneurysm and detached by electrolysis. Subsequent

development of variable stiffness microcatheters and steerable microwires capable of navigating the tortuous intracranial circulation, led to an exponential growth in the field of endovascular neurosurgery. A multitude of different coils with various sizes (diameters and lengths), predetermined shapes, degrees of softness, delivery systems, and biological coatings have since been developed. In a brief time span, endovascular coiling became the preferred treatment modality for most ruptured and unruptured intracranial aneurysms.

The International Subarachnoid Aneurysm Trial (ISAT), a randomized, controlled, prospective study comparing both endovascular and surgical aneurysm treatment options revealed survival free of disability at 1 year is significantly better with endovascular coiling. The data also suggested that the long-term risks of further bleeding from the treated aneurysm are low with either therapy, although somewhat more frequent with endovascular coiling<sup>14</sup>.

Recently published BRAT study evaluating the superiority in safety and efficacy of clipping versus endovascular coiling for the treatment of ruptured cerebral aneurysms also observed a better 1-year outcome in patients treated with coil embolization in comparison to microsurgical clipping and no recurrent hemorrhage was seen after aneurysmal coil embolization<sup>15</sup>.

Today, endovascular treatment has become the treatment of choice for both ruptured and unruptured intracranial aneurysms. Over the past two decades, the access system, microcatheters, microguide wires and embolic materials along with management strategies have significantly improved and are still evolving.

### Decision making in Intracranial Aneurysm Treatment

Intracranial aneurysms are quite heterogeneous with regards to patients age, their status at presentation (ruptured versus unruptured), aneurysm shape (fusiform versus saccular) and location (aneurysm geometry in relationship to parent artery), their size (small/large/giant), the size of their neck (small/

large), and associated systemic disorders. The heterogeneity is made more complex by the availability of various treatment options including surgery and rapidly improving endovascular treatment options.

In general, any ruptured aneurysm warrants treatment provided patient is in a fair neurological status. Decision-making on treatment of unruptured intracranial aneurysm is difficult. The following principles serve as guidelines in the treatment of most simple aneurysms<sup>16</sup>.

### Patients under the age of 60 years

For small (<7 mm) anterior circulation aneurysms, conservative medical management, with aggressive treatment of risk factors such as smoking and hypertension, can be considered. Exceptions include patients with a strong family history of subarachnoid hemorrhage, a symptomatic aneurysm, a daughter sac, or aneurysms at potentially high-risk locations, including the posterior communicating artery origin and possibly the anterior communicating artery.

For small (<7mm) posterior circulation aneurysm, treatment should be considered if it could be undertaken with a low risk of complications.

For those aneurysms that are 7 mm or greater in size, treatment is typically recommended; the choice of intervention is dependent on aneurysm size, location, and other morphology characteristics, and the patient's clinical state.

Interventional treatment should probably be undertaken for large unruptured intracranial aneurysms and those that are symptomatic, particularly in young patients.

As intervention risks generally increase with age, a conservative approach to treatment of elderly patients is indicated, particularly for small aneurysms. Surgical morbidity is lowest under the age of 50–60 years.

In patients undergoing endovascular therapy, age is not as strongly related to risk of morbidity and mortality.

### Patients over the age of 60 Years

For small (<7 mm) aneurysms, conservative management is usually recommended except in those with a strong family history of subarachnoid hemorrhage or a symptomatic aneurysm.

For aneurysms of 7–12 mm in diameter, management is individualized. Aneurysms in the anterior circulation can be considered for conservative management. Aneurysms in the posterior circulation or posterior communicating artery should be strongly considered for interventional management.

For aneurysms greater than 12 mm in diameter, an interventional procedure should be strongly considered, taking into account the patient's overall health status and presence of factors that might increase surgical or endovascular risks.

Patients treated conservatively should be counseled about potential risk factors for aneurysm growth and rupture. These risk factors include hypertension and tobacco use. Aggressive control of hypertension and smoking cessation should be strongly advocated for all such patients. They should also be advocated on the need for follow up vascular imaging using CT angiogram or MR angiogram.

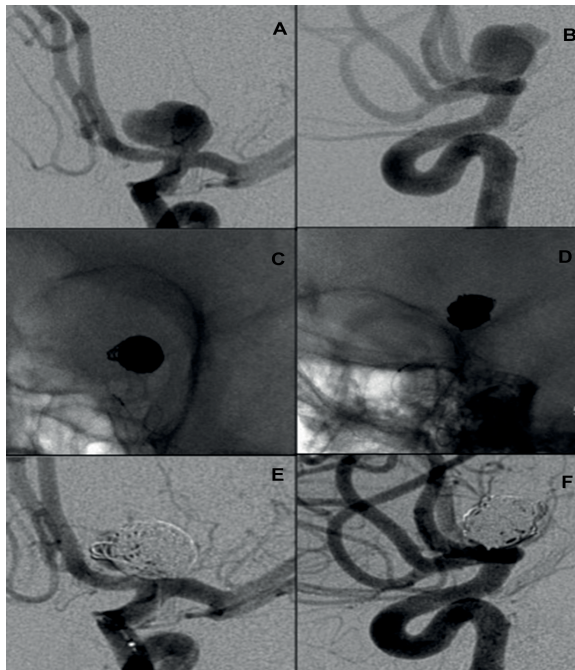
### Endovascular Treatment

Endovascular embolization is the treatment of choice for intracranial aneurysm. Since the introduction of electrolytically detachable platinum coils, coil embolization is accepted as an optimal minimally invasive treatment option. Initial large series showed acceptable mortality and morbidity (4%–9%), related mostly to thromboembolic complications and intraoperative rupture<sup>17,18</sup>. Further larger series confirmed the feasibility of aneurysm coiling (96.9% in ruptured aneurysms and 94.0% in unruptured aneurysms), with acceptable procedural mortality (1.4% in ruptured and 1.7% in unruptured aneurysms) and morbidity rates (8.6% in ruptured and 7.7% in unruptured aneurysms)<sup>19,20</sup>. Various treatment options include–

1. Coil embolization.
2. Balloon assisted coil embolization(BAC)
3. Stent assisted coil embolization (SAC)
4. Flow diversion
5. Flow disruption
6. Embolization using liquid embolic agents (LEA)
7. Parent artery occlusion

### Coil embolization

Most aneurysms (about 75%) have narrow neck with dome to neck ratio (maximum dome width/maximum neck width) of more than 1.6 which is amenable for endovascular CE without any assistance<sup>21</sup>. Endovascular access is gained via placement of a femoral sheath. This approach is a minimally invasive technique in which a microcatheter is placed into the aneurysm lumen and platinum coils that come in different shapes, sizes, softness and coil diameters are delivered to support thrombus formation. Detachment of the coils occurs either mechanically or electrolytically. Initially framing coils followed by filling coils are used to achieve good packing of the aneurysm. During aneurysm coiling, the most frequent complication that can happen includes thromboembolic complications and intraoperative rupture of the aneurysm. In unruptured aneurysms, the rates of thromboembolic complications and intraoperative rupture were reported at 7.3% and 2.0%, respectively<sup>22</sup> while, in ruptured aneurysms, they were higher at 13.3% and 3.7%, respectively<sup>23</sup>. To prevent thromboembolic complications, most operators use intravenous heparin before coil deployment in unruptured aneurysm and after the first few coils in ruptured aneurysm<sup>24</sup> (Fig 1).



**Fig 1: Internal carotid artery bifurcation aneurysm with a narrow neck AP (A) and Lateral view (B). Treated by primary coil embolization and the radio opaque coil mass is seen in native images (C & D). Immediate post treatment angiogram shows the obliteration of aneurysm with stagnation of residual flow in the aneurysm. (E & F).**

Following coil embolization, persistent and durable occlusion is not achieved in all aneurysms. It is estimated by systematic review that aneurysm recanalization occurs in up to 25% and retreatment in 10.3% of cases<sup>25</sup>. Recanalization of the aneurysm may be due to coil compaction or regrowth of the aneurysm and various factors that may be associated with this include high blood pressure, smoking, aneurysm diameter and neck size, and quality of immediate postoperative aneurysm occlusion as decided by coil packing density<sup>26-30</sup>. To reduce the recanalization rate various modifications were made, that include: Coating of the coil with bioactive Polyglycolic/poly(lactic acid) (PGLA), absorbable copolymer (matrix coil), interwoven PGLA microfilaments (Nexus coils), filling the inner core with hydrogel (Hydro coil) that swell on exposure to blood to improve packing density. Mid and long term follow up evaluation of these coils in multicenter series showed no benefit in preventing recanalization compared to bare platinum coils<sup>9,31-33</sup>. Incompletely coiled or recanalized aneurysms have an increased risk of rehemorrhage compared with those that are completely occluded and therefore require long-term follow-up angiography. Post procedural rebleeding is an infrequent complication and carries a high mortality<sup>34, 35</sup>.

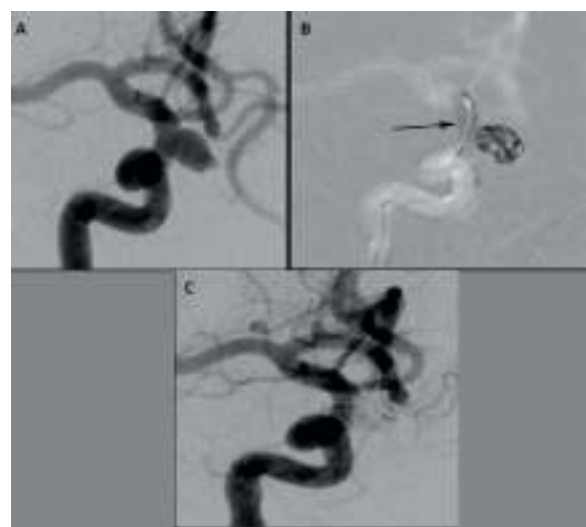### Balloon assisted coil embolization (BAC)

Aneurysms with dome to neck ratio of less than 1.6 require some assistance at the base of the aneurysm either temporarily during coiling or permanently for successful embolization. In 1997, Moret et al described the technique to coiling wide neck aneurysm with remodeling using balloon. Since then balloon

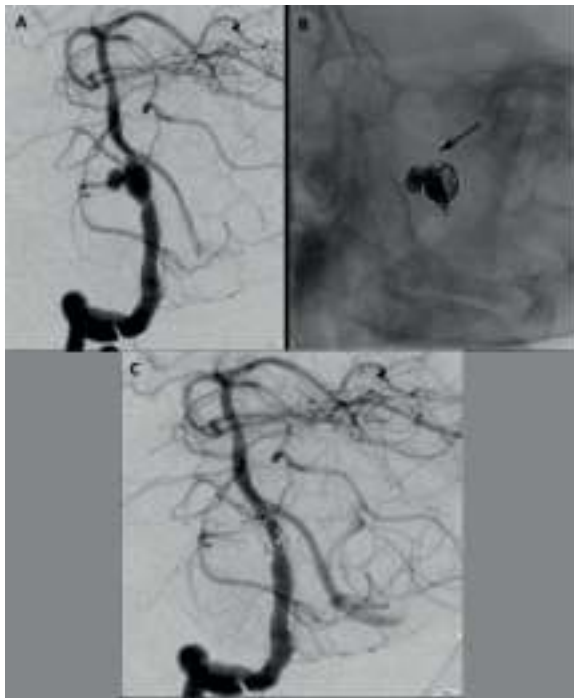remodeling has been used in different locations including bifurcation aneurysm and for different shapes of the aneurysm. The balloon is inflated during the coil placement and deflated right after. During inflation of the balloon, there is temporary occlusion of the parent artery so the patient needs to be adequately anti-coagulated to prevent thromboembolic complications. Initially a round balloon was used, now in most cases, a hyper-compliant sausage shaped balloon is used. Recently a double lumen balloon was introduced that enables the use of stent in the end if the coils placed within the aneurysm remain unstable and also prevents the coils from prolapsing between the stent struts. BAC is not only used to enable coiling, but also as a bailout in case of an intraoperative aneurysm rupture during coiling. The balloon stays deflated across the neck of the aneurysm and is inflated only in case of intraoperative rupture. Santillan et al have demonstrated that in the setting of intraoperative rupture, BAC was associated with a higher probability of unchanged or improved clinical outcome as compared with standard coiling<sup>36</sup>. The rates of thromboembolic events in both ruptured and unruptured aneurysms are the same with or without balloon use during the procedure. But, the rupture rate is relatively higher in the balloon group (3.2% vs. 2.2%)<sup>37</sup>. In general, if used judiciously in selected cases, it is a safe and useful tool for better treatment in wide neck aneurysms as it avoids the use of stent and long-term antiplatelet treatment (Fig 2&3).

### Stent assisted Coil embolization (SAC)

Stent is a metal scaffold placed across the neck of the aneurysm for effective embolization of wide neck, large to giant, and fusiform aneurysms. Initially coronary stents were used and the reports date back to as early as 1998. Later dedicated neurovascular stent systems were developed using much thinner and lightweight titanium metal.



**Fig 2: Oblique angiogram of internal carotid artery showing a broad based superior hypophyseal artery aneurysm (A). Balloon assisted embolization is performed (B), the inflated balloon in the parent artery is shown with an arrow. Post embolization angiogram shows complete obliteration of the aneurysm (C).**



**Fig 3:** Dysplastic ruptured vertebral artery aneurysm (A) is treated by stent assisted coil embolization. The radio opaque stent struts are shown with an arrow (B). Post embolization angiogram shows complete obliteration of the aneurysm with preserved flow in the parent artery. (C)

In general, stent is avoided in patients with acutely ruptured aneurysm and reserved for patients with unruptured aneurysm. A foreign body left in blood stream will result in thrombosis, and in order to prevent it, preoperative and postoperative antiplatelet treatment is essential. Aspirin and Clopidogrel are the preferred anti-platelets and their inhibition of platelet function is monitored to assess their therapeutic effect. In resistant patients Prasugrel is the next choice anti-platelet. Stent assistance allows the surgeon to spack the aneurysm better along with the residual tiffness of the stent resulting in reorientation of the vessel and reduction in hemodynamic stress contributes to lesser recanalization. In one of the early largest series, though stent was used for difficult and complex aneurysms, stent use was associated with higher rates of permanent neurological complications (7.4%) as compared with standard coiling (3.8%). Procedure related mortality in the stenting group was 4.6% versus 1.2% in the non-stenting group. However the recurrence was significantly lower in the stenting group 14.9% as against 33.5% in the non-stenting group<sup>38</sup>.

More recently multicenter studies from United States and Europe show better and similar results. Periprocedural complication rate was around 12% in particular thromboembolic events happened in 4.4% and 3.7% respectively. The complete occlusion rate after the procedure was 60% to 66.4%, respectively. An additional 14% of the treated aneurysms showed a progressive occlusion at 12 to 18 months follow-up; aneurysm recurrence rate was around 10%. Subsequently 8% and 4% of the aneurysms were retreated in respective studies<sup>39, 40</sup>.

Now, with gaining experience during the past years, stenting is more frequently used in acutely ruptured aneurysms however, the hemorrhagic complications are higher with this approach. One of the reviews have noted intracranial hemorrhagic complications in 8% including EVDs related hemorrhages. Clinically significant thromboembolic events occurred in 6%. Sixty-seven percent of patients had favorable clinical outcomes, 14% had poor outcomes, and 19% died<sup>41</sup>.

## Flow Diversion

Flow diverters have expanded the therapeutic options for treatment of cerebral aneurysms and represent a welcomed paradigm shift. Previously untreatable intracranial aneurysms can now be safely treated.

Flow diverters are low porosity, tight meshed tubular stents when placed in the parent artery across the base of the aneurysm result in parent vessel reconstruction, aneurysm obliteration with preservation of side branches. Preclinical studies have shown good clinical efficacy<sup>42</sup>. The mesh has a metal coverage of about 30% to 40% of the surface area and the pores are strategized to provide flow redirection ie, increased impedance of the stent reduces the blood flow into the aneurysm leading to slow, progressive and stable thrombus formation along with diversion of flow into the parent artery. High flow and demand in the side branches keep them open. Over time, the meshwork provides a scaffold for neo-endothelialization across the aneurysm neck. In contrast to the traditional intrasaccular aneurysm treatment, there often remains a residual post-interventional filling of the aneurysm sac, which will subside over a period of months (Fig 4).

Flow diverters are used to treat complex aneurysms, including wide neck, large and giant aneurysms, fusiform aneurysms, dysplastic and recanalized aneurysms following previous treatment. Currently four flow diverters are available for clinical use. Pipeline Embolization Device (EV3-MTI, Irvine, CA), Silk (Balt, Montmorency, France), Surpass (Stryker, Fremont, CA) and FRED (Microvention, Tustin, CA). Initial small series from one or few centers were promising with technical feasibility and its safety with acceptable complication rate<sup>43-47</sup>. Subsequent large series both retrospective and prospective from single and multicenter have shown similar results to substantiate its clinical use<sup>48-50</sup>. Recently a prospective multinational multicenter series confirmed the high efficacy of flow diverters with technical feasibility of 99.1% with acceptable safety profile (5.6% of patients had major ipsilateral stroke or neurological death)<sup>51</sup>.

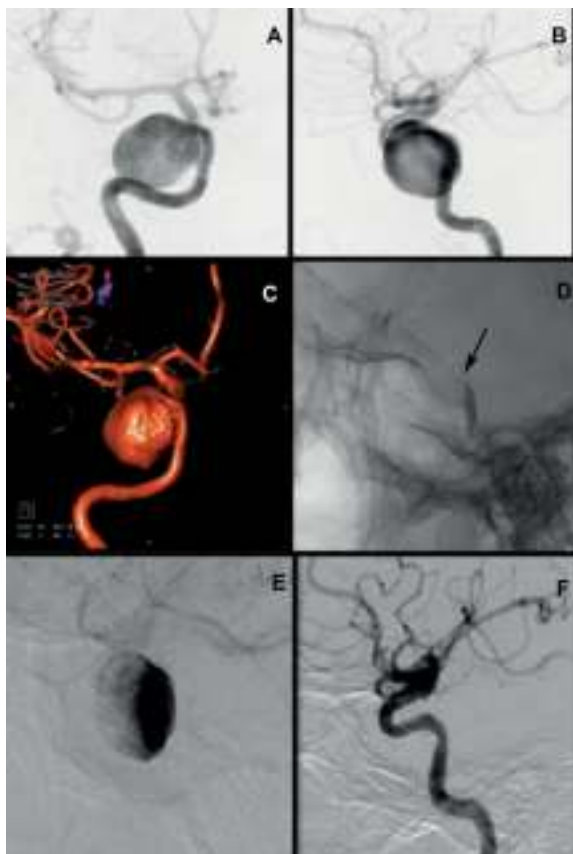
Flow diverter use currently is limited for difficult unruptured aneurysms, as it requires dual antiplatelet medication. However, there is a series to suggest its use in small-ruptured blister like aneurysm that cannot be treated by standard coil embolization<sup>52</sup>. Due to the higher metal coverage in Flow diverters, there is an increased incidence of thromboembolism in spite of the dual antiplatelet. Delayed rupture of the aneurysm has been reported and its incidence is about 1% but its mechanism is unknown. Hemodynamic alteration leading to altered focal stress within the aneurysm,



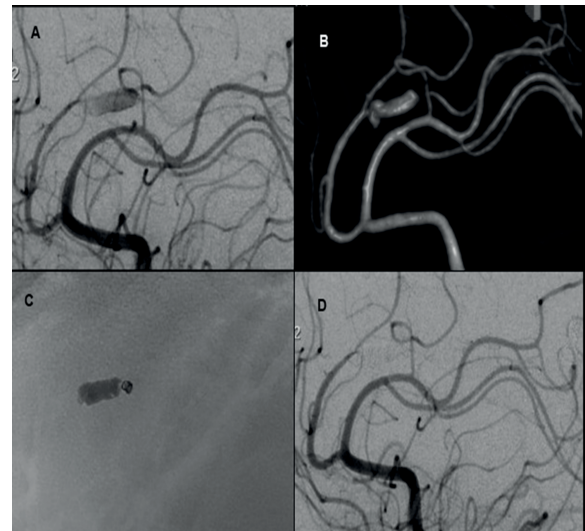
along with large unstable aneurysmal thrombus created by flow reduction, may result in inflammation and weakening of the aneurysm wall, have been proposed as mechanisms and it largely remains speculative<sup>53,54</sup>. To prevent delayed rupture, suggestions have been made to place coils within the aneurysm and use of periprocedural steroids have been proposed.

Delayed and remote ipsilateral intraparenchymal hemorrhage is reported and its incidence is not known. Its mechanism is largely unknown but the proposed mechanisms include hemorrhagic transformation of small ischemic lesions, higher blood flow with altered auto regulation, along with dual antiplatelets contribute to massive hemorrhage.

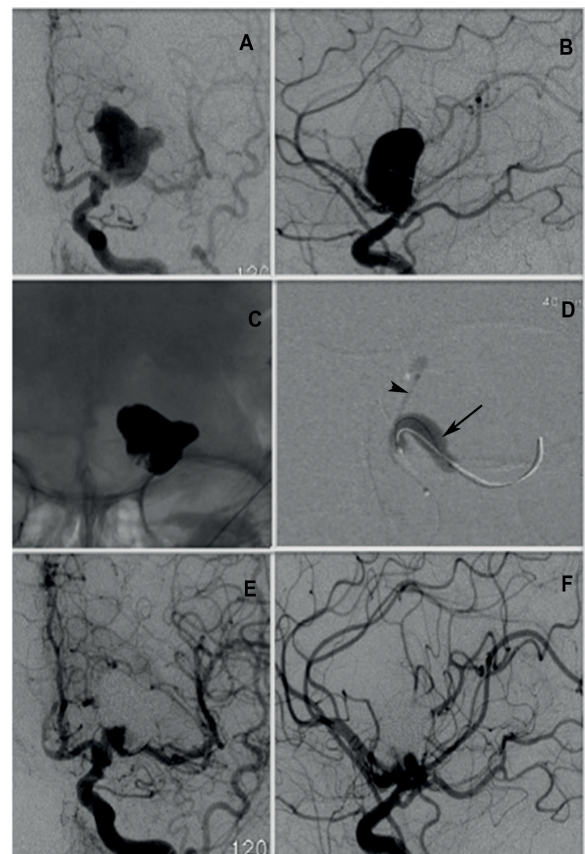
Flow diverters have been in clinical use only for the past few years, the initial experience is promising and has provided effective and simple solution to complex and difficult aneurysms. The safety profile is acceptable in such high-risk situations. Its use for simple aneurysms is yet to be proven. Flow diverters use has reignited the need for research of safer and more efficacious use of antiplatelet in elective and emergent endovascular techniques (Fig 5&6).



**Fig 4:** Giant cavernous carotid artery aneurysm presented with ocular cranial neuropathy in shown AP (A), Lateral (B) and 3D projections (C). The aneurysm was treated by flow diverter, which is shown in the native image with an arrow (D). Immediate post treatment angiogram shows contrast stagnation within the aneurysm (E). Six months follow up angiogram shows complete obliteration of the aneurysm with remodeling of the parent artery (F).



**Fig 5:** Pericallosal dysplastic mycotic aneurysm (A) in lateral angiogram and 3D angiogram (B) treated by n-BCA embolization with coils to prevent forward migration of the liquid embolic (C). Control angiogram reveals total obliteration of the aneurysm and the dysplastic segment of the artery (D).



**Fig 6:** M1 segment large aneurysm with broad base in AP (A) and Lateral (B) projections. The aneurysm is treated by balloon assisted Onyx embolization (D), the inflated balloon is shown by arrow and the Onyx injection catheter is shown by arrow head. Final Onyx cast in native image (C) is shown. Post embolization angiogram reveals obliteration of the aneurysm with minimal residual filling at the base of the aneurysm in AP (E) and Lateral (F) projections.

## Intra aneurysmal flow diversion or Flow Disruption

Intra-aneurysmal flow disruption or flow diversion is an endovascular approach where a device is deployed within the aneurysm to create blood flow stasis with subsequent thrombosis. There is no need for antiplatelet medication and therefore can be safely used for ruptured aneurysms. Preclinical studies have shown the feasibility of this approach as well as its safety and efficacy<sup>55</sup>. Currently available devices include WEB and Luna. The WEB device is well suited for the treatment of wide-neck bifurcation aneurysms of the basilar artery, the middle cerebral artery, the anterior communicating artery, and the internal carotid artery. In an initial retrospective, multicenter series using WEB device the technical success rate was 100% with an acceptable morbidity of 4.8%<sup>56</sup>. Subsequent prospective, single-center series showed similar results<sup>57</sup>.

## Embolization With Liquid Embolic Material

An aneurysm being a 3 dimensional space, volume filling with a liquid that will subsequently become solid to take the shape of the aneurysm is the most definitive way to achieve maximal occlusion. With this concept, High density Onyx (ethylene vinyl alcohol copolymer dissolved in dimethyl sulfoxide) - a liquid embolic system, was developed and used for the treatment of intracranial aneurysms<sup>58-60</sup>. Its use involves placement of a balloon across the neck of the aneurysm while Onyx is injected endosaccularly. This procedure is technically challenging with significant limitations. The challenges include: leakage across the balloon into the parent artery resulting in narrowing of the parent artery, catheter entrapment, potential space between the onyx cast and aneurysmal wall as Onyx is more cohesive than adhesive<sup>61</sup>. Though initial results in complex aneurysms were acceptable with good safety and efficacy<sup>62</sup> technical challenges and safety concerns interrupted the development of this technique<sup>63</sup>.

## Parent artery Occlusion

Giant and dysplastic aneurysms are difficult aneurysms to treat. Parent vessel occlusion following balloon test occlusion with or without extra cranial and intracranial bypass is considered as an acceptable solution. Now, with the introduction of flow diverters most such aneurysms are treated effectively without vessel sacrifice. Parent occlusion has become almost obsolete with few exceptions like distally located mycotic aneurysms, high-flow caroticocavernous fistula due to ruptured cavernous aneurysms, flow related pre-nidal aneurysms in the feeder of an AVM.

## Complications associated with endovascular treatment of intracranial aneurysms

Endovascular treatment of intracranial aneurysm is a demanding procedure that requires a specific skill set and attention to finer details during the procedure to

avoid complications related to the procedure. It may be mild or have devastating consequences if not identified or no corrective measures are taken. Overall complication rates varies significantly based on the experience of the surgeon and has been reported to range from 11.3%-19.4%<sup>64</sup>.

## Aneurysm Perforation

Aneurysm perforation can occur during any part of the procedure, typically occurring in a small aneurysm during intra aneurysmal manipulation with microwire, microcatheter, or coil. Aneurysm perforation has been reported in 2.5%-5.4%. A meta-analysis by Cloft et al found the risk of perforation to be significantly higher in ruptured aneurysms than in unruptured aneurysms (4.1% vs. 0.7%)<sup>65</sup>. In a more recent meta-analysis in patients with aneurysms of  $\leq 3$  mm, the intraprocedural rupture rate in unruptured aneurysms was found to be 5.0% compared to 10.7% in small-ruptured aneurysms<sup>66</sup>.

In the event of an intra-procedural aneurysm rupture, there is sudden systemic hemodynamic alteration. Confirmation is done by angiogram that reveal leakage of contrast. The heparin on board is reversed with Protamine. The goal in this situation is to rapidly occlude the aneurysm, by placing coils taking into account that a segment of the coil may extrude into the sub arachnoid space. If balloon assistance is in place, taking advantage to inflate the balloon will help to temporarily arrest bleeding.

## Thromboembolic Events

Thromboembolic events are commonest complication of an endovascular aneurysmal treatment. This includes silent DWI changes seen following aneurysm coiling that occurs in about 42% of patients<sup>67</sup>. Periprocedural thromboembolic events do happen as the coils we use for occlusion is highly thrombogenic. They mostly happen at the base of the aneurysm extending into the parent artery. As a preventive measure, the patient is heparinized to maintain the ACT at 2-3 times the normal range. In ruptured aneurysms heparin is given after the placement of first coil. Factors that influence thrombosis as evidenced by the CLARITY study, a higher rate of thromboembolic events was observed in patients with large aneurysms ( $>10$  mm), in smokers, and in aneurysms with a neck larger than 4 mm<sup>68</sup>. managed by using, abciximab (ReoPro), a glycoprotein IIb/IIIa receptor antagonist that inhibits platelet aggregation. It has a short plasma half-life. Platelet aggregation returns to normal in about 96-120 hours after discontinuation. Interventional techniques like the Penumbra aspiration catheter with separator or stent-trievers can also be used to re-open an occluded vessel.

## Device Failure

**Stretching:** Currently the coils used for coiling are all stretch resistant with tiny filaments extending between the two ends of the coil to prevent it from unraveling unintentionally when pulled on. Excess manipulation can result in stretching of the coil and the reported rate during embolization varies between 0.2%-6.5%<sup>19,69</sup>.

**Failure to detach and premature detachment of the coils:** Failure of the coil to detach is easily managed as the coil can still be retrieved while premature coil detachment can lead to coil being lodged in the parent artery. In such a situation, it can be pushed into the aneurysm with a pusher wire but repositioning is impossible.

**Coil herniation:** Coil herniation happens when the coil is extruded out of the aneurysm into the parent artery during coiling. The reported incidence is 2.4%-4.2%<sup>69</sup>. It is associated with detachment of unstable coil moving with pulsatile blood flow, larger or longer coils, excessive packing of the aneurysm and wide neck aneurysm. Coil herniation can induce parent artery thrombosis, emboli and lead to ischemic complications<sup>70,71</sup>.

**Coil migration:** Coil migration happens in wide-necked aneurysms due to unstable coil position, undersized coils and under packing of the aneurysm. Its incidence is reported in about 0.5%-1.7%.<sup>17,72</sup> Stent- or balloon-assistance can reduce the risk of coil herniation or migration.

## Dissection

A dissection develops due to tear in the tunica intima, the innermost layer of the arterial wall and blood enters this newly formed space leading to progressive separation of the inner lining and may cause stenosis or even complete occlusion of the true vessel lumen. Periprocedurally, vessel dissection is caused by catheter and wire manipulation and has been reported in 0.26% of cases<sup>73</sup>. If the dissection is flow limiting with poor collaterals, it is necessary to place a stent else most dissections are treated with heparin in the acute phase and later with aspirin or clopidogrel.

## Conclusion

In summary, most intracranial aneurysms today can be treated by endovascular technique. Endovascular approaches available for the treatment include standard coiling, balloon assisted coiling, stent assisted coiling, flow diversion, flow disruption, embolization by liquid embolic agents and parent artery occlusion. Ruptured aneurysms are treated emergently to prevent rebleeding and effectively manage complications associated with subarachnoid hemorrhage like vasospasm and hydrocephalus. Not all unruptured aneurysms need to be treated. Management decisions are made on a case-by-case basis, taking into account clinical presentation, age, associated comorbidities as well as aneurysm location, morphology and size. In general, aneurysms with small neck are treated by standard coiling or balloon assisted coiling while wide neck, large and giant, and fusiform, aneurysms, are treated by stent assisted coiling, or by use of flow diverter or flow disruption. Advances in imaging technology and device manufacturing have resulted in safe and effective management of most intracranial aneurysms by endovascular route.

## References

- 1) Vlak MH, Algra A, Brandenburg R, Rinkel GJ. Prevalence of unruptured intracranial aneurysms, with emphasis on sex, age, comorbidity, country, and time period: a systematic review and meta-analysis. *Lancet neurology*. 2011;10(7):626-36.
- 2) Jellinger K. Pathology of intracerebral hemorrhage. *Zentralblatt fur Neurochirurgie*. 1977;38(1):29-42.
- 3) Jakubowski J, Kendall B. Coincidental aneurysms with tumours of pituitary origin. *Journal of neurology, neurosurgery, and psychiatry*. 1978;41(11):972-9.
- 4) Wardlaw JM, White PM. The detection and management of unruptured intracranial aneurysms. *Brain : a journal of neurology*. 2000;123 ( Pt 2):205-21
- 5) Morita A, Kirino T, Hashi K, Aoki N, Fukuhara S, et al. The natural course of unruptured cerebral aneurysms in a Japanese cohort. *The New England journal of medicine*. 2012;366(26):2474-82.
- 6) Kassell NF, Torner JC, Jane JA, Haley EC, Jr., Adams HP. The International Cooperative Study on the Timing of Aneurysm Surgery. Part 2: Surgical results. *Journal of neurosurgery*. 1990;73(1):37-47.
- 7) Dandy WE. Intracranial Aneurysm of the Internal Carotid Artery: Cured by Operation. *Annals of surgery*. 1938;107(5):654-9.
- 8) Serbinenko FA. Balloon catheterization and occlusion of major cerebral vessels. *Journal of neurosurgery*. 1974;41(2):125-45.
- 9) White PM, Lewis SC, Gholkar A, Sellar RJ, Nahser H, Cognard C, et al. Hydrogel-coated coils versus bare platinum coils for the endovascular treatment of intracranial aneurysms (HELPS): a randomised controlled trial. *Lancet*. 2011;377(9778):1655-62.
- 10) Higashida RT, Halbach VV, Cahan LD, Hieshima GB, Konishi Y. Detachable balloon embolization therapy of posterior circulation intracranial aneurysms. *Journal of neurosurgery*. 1989;71(4):512-9.
- 11) Guglielmi G, Vinuela F, Dion J, Duckwiler G. Electrothrombosis of saccular aneurysms via endovascular approach. Part 2: Preliminary clinical experience. *Journal of neurosurgery*. 1991;75(1):8-14.
- 12) Guglielmi G, Vinuela F, Sepetka I, Macellari V. Electrothrombosis of saccular aneurysms via endovascular approach. Part 1: Electrochemical basis, technique, and experimental results. *Journal of neurosurgery*. 1991;75(1):1-7.

- 13) Guglielmi G. History of the genesis of detachable coils. A review. *Journal of neurosurgery*. 2009;111(1):1-8.
- 14) Molyneux A, Kerr R, Stratton I, Sandercock P, Clarke M, Shrimpton J, et al. International Subarachnoid Aneurysm Trial (ISAT) of neurosurgical clipping versus endovascular coiling in 2143 patients with ruptured intracranial aneurysms: a randomised trial. *Lancet*. 2002;360(9342):1267-74.
- 15) McDougall CG, Spetzler RF, Zabramski JM, Partovi S, Hills NK, Nakaji P, et al. The Barrow Ruptured Aneurysm Trial. *Journal of neurosurgery*. 2012;116(1):135-44.
- 16) Brown RD, Jr., Broderick JP. Unruptured intracranial aneurysms: epidemiology, natural history, management options, and familial screening. *Lancet neurology*. 2014;13(4):393-404.
- 17) Vinuela F, Duckwiler G, Mawad M. Guglielmi detachable coil embolization of acute intracranial aneurysm: perioperative anatomical and clinical outcome in 403 patients. *Journal of neurosurgery*. 1997;86(3):475-82.
- 18) Cognard C, Weill A, Castaings L, Rey A, Moret J. Intracranial berry aneurysms: angiographic and clinical results after endovascular treatment. *Radiology*. 1998;206(2):499-510.
- 19) Gallas S, Pasco A, Cottier JP, Gabrillargues J, Drouineau J, Cognard C, et al. A multicenter study of 705 ruptured intracranial aneurysms treated with Guglielmi detachable coils. *AJNR*. 2005;26(7):1723-31.
- 20) Gallas S, Drouineau J, Gabrillargues J, Pasco A, Cognard C, Pierot L, et al. Feasibility, procedural morbidity and mortality, and long-term follow-up of endovascular treatment of 321 unruptured aneurysms. *AJNR*. 2008;29(1):63-8.
- 21) Brinjikji W, Cloft HJ, Kallmes DF. Difficult aneurysms for endovascular treatment: overdue or undertall? *AJNR*. 2009;30(8):1513-7.
- 22) Pierot L, Spelle L, Vitry F, Investigators A. Immediate clinical outcome of patients harboring unruptured intracranial aneurysms treated by endovascular approach: results of the ATENA study. *Stroke; a journal of cerebral circulation*. 2008;39(9):2497-504.
- 23) Cognard C, Weill A, Spelle L, Piotin M, Castaings L, Rey A, et al. Long-term angiographic follow-up of 169 intracranial berry aneurysms occluded with detachable coils. *Radiology*. 1999;212(2):348-56.
- 24) Ries T, Buhk JH, Kucinski T, Goebell E, Grzyska U, Zeumer H, et al. Intravenous administration of acetylsalicylic acid during endovascular treatment of cerebral aneurysms reduces the rate of thromboembolic events. *Stroke; a journal of cerebral circulation*. 2006;37(7):1816-21.
- 25) Ferns SP, Sprengers ME, van Rooij WJ, Rinkel GJ, van Rijn JC, Bipat S, et al. Coiling of intracranial aneurysms: a systematic review on initial occlusion and reopening and retreatment rates. *Stroke; a journal of cerebral circulation*. 2009;40(8):e523-9.
- 26) Hope JK, Byrne JV, Molyneux AJ. Factors influencing successful angiographic occlusion of aneurysms treated by coil embolization. *AJNR*. 1999;20(3):391-9.
- 27) Ortiz R, Stefanski M, Rosenwasser R, Veznedaroglu E. Cigarette smoking as a risk factor for recurrence of aneurysms treated by endosaccular occlusion. *Journal of neurosurgery*. 2008;108(4):672-5.
- 28) Choi DS, Kim MC, Lee SK, Willinsky RA, Terbrugge KG. Clinical and angiographic long-term follow-up of completely coiled intracranial aneurysms using endovascular technique. *Journal of neurosurgery*. 2010;112(3):575-81.
- 29) Wakhloo AK, Gounis MJ, Sandhu JS, Akkawi N, Schenck AE, Linfante I. Complex-shaped platinum coils for brain aneurysms: higher packing density, improved biomechanical stability, and midterm angiographic outcome. *AJNR*. 2007;28(7):1395-400.
- 30) Pierot L, Cognard C, Anxionnat R, Ricolfi F, Investigators C. Endovascular treatment of ruptured intracranial aneurysms: factors affecting midterm quality anatomic results: analysis in a prospective, multicenter series of patients (CLARITY). *AJNR*. 2012;33(8):1475-80.
- 31) Pierot L, Cognard C, Ricolfi F, Anxionnat R, investigators C. Mid-term anatomic results after endovascular treatment of ruptured intracranial aneurysms with Guglielmi detachable coils and Matrix coils: analysis of the CLARITY series. *AJNR*. 2012;33(3):469-73.
- 32) Molyneux AJ, Clarke A, Sneade M, Mehta Z, Coley S, Roy D, et al. Cerecyte coil trial: angiographic outcomes of a prospective randomized trial comparing endovascular coiling of cerebral aneurysms with either cerecyte or bare platinum coils. *Stroke; a journal of cerebral circulation*. 2012;43(10):2544-50.
- 33) Roth C, Struffert T, Grunwald IQ, Romeike BF, Krick C, Papanagiotou P, et al. Long-term results with Matrix coils vs. GDC: an angiographic and histopathological comparison. *Neuroradiology*. 2008;50(8):693-9.
- 34) Eljovich L, Higashida RT, Lawton MT, Duckwiler G, Giannotta S, Johnston SC, et al. Predictors and outcomes of intraprocedural rupture in patients treated for ruptured intracranial aneurysms: the



- CARAT study. *Stroke; a journal of cerebral circulation*. 2008;39(5):1501-6.
- 35) Aikawa H, Kazekawa K, Nagata S, Onizuka M, Iko M, Tsutsumi M, et al. Rebleeding after endovascular embolization of ruptured cerebral aneurysms. *Neurologia medico-chirurgica*. 2007;47(10):439-45; discussion 46-7.
- 36) Santillan A, Gobin YP, Greenberg ED, Leng LZ, Riina HA, Stieg PE, et al. Intraprocedural aneurysmal rupture during coil embolization of brain aneurysms: role of balloon-assisted coiling. *AJNR* 2012;33(10):2017-21.
- 37) Pierot L, Spelle L, Leclerc X, Cognard C, Bonafe A, Moret J. Endovascular treatment of unruptured intracranial aneurysms: comparison of safety of remodeling technique and standard treatment with coils. *Radiology*. 2009;251(3):846-55.
- 38) Piotin M, Blanc R, Spelle L, Mounayer C, Piantino R, Schmidt PJ, et al. Stent-assisted coiling of intracranial aneurysms: clinical and angiographic results in 216 consecutive aneurysms. *Stroke; a journal of cerebral circulation*. 2010;41(1):110-5.
- 39) Fargen KM, Hoh BL, Welch BG, Pride GL, Lanzino G, Boulos AS, et al. Long-term results of enterprise stent-assisted coiling of cerebral aneurysms. *Neurosurgery*. 2012;71(2):239-44; discussion 44.
- 40) Gentric JC, Biondi A, Piotin M, Mounayer C, Lobotesis K, Bonafe A, et al. Safety and efficacy of neuroform for treatment of intracranial aneurysms: a prospective, consecutive, French multicentric study. *AJNR* 2013;34(6):1203-8.
- 41) Bodily KD, Cloft HJ, Lanzino G, Fiorella DJ, White PM, Kallmes DF. Stent-assisted coiling in acutely ruptured intracranial aneurysms: a qualitative, systematic review of the literature. *AJNR* 2011;32(7):1232-6.
- 42) Sadasivan C, Cesar L, Seong J, Rakian A, Hao Q, Tio FO, et al. An original flow diversion device for the treatment of intracranial aneurysms: evaluation in the rabbit elastase-induced model. *Stroke; a journal of cerebral circulation*. 2009;40(3):952-8.
- 43) Lylyk P, Miranda C, Ceratto R, Ferrario A, Scrivano E, Luna HR, et al. Curative endovascular reconstruction of cerebral aneurysms with the pipeline embolization device: the Buenos Aires experience. *Neurosurgery*. 2009;64(4):632-42; discussion 42-3; quiz N6.
- 44) Szikora I, Berentei Z, Kulcsar Z, Marosfoi M, Vajda ZS, Lee W, et al. Treatment of intracranial aneurysms by functional reconstruction of the parent artery: the Budapest experience with the pipeline embolization device. *AJNR* 2010;31(6):1139-47.
- 45) Byrne JV, Beltechi R, Yarnold JA, Birks J, Kamran M. Early experience in the treatment of intra-cranial aneurysms by endovascular flow diversion: a multicentre prospective study. *PloS one*. 2010;5(9).
- 46) Lubicz B, Collignon L, Raphaeli G, Pruvo JP, Bruneau M, De Witte O, et al. Flow-diverter stent for the endovascular treatment of intracranial aneurysms: a prospective study in 29 patients with 34 aneurysms. *Stroke; a journal of cerebral circulation*. 2010;41(10):2247-53.
- 47) Berge J, Biondi A, Machi P, Brunel H, Pierot L, Gabrillargues J, et al. Flow-diverter silk stent for the treatment of intracranial aneurysms: 1-year follow-up in a multicenter study. *AJNR* 2012;33(6):1150-5.
- 48) Kan P, Siddiqui AH, Veznedaroglu E, Liebman KM, Binning MJ, Dumont TM, et al. Early postmarket results after treatment of intracranial aneurysms with the pipeline embolization device: a U.S. multicenter experience. *Neurosurgery*. 2012;71(6):1080-7; discussion 7-8.
- 49) Piano M, Valvassori L, Quilici L, Pero G, Boccardi E. Midterm and long-term follow-up of cerebral aneurysms treated with flow diverter devices: a single-center experience. *Journal of neurosurgery*. 2013;118(2):408-16.
- 50) O'Kelly CJ, Spears J, Chow M, Wong J, Boulton M, Weill A, et al. Canadian experience with the pipeline embolization device for repair of unruptured intracranial aneurysms. *AJNR* 2013;34(2):381-7.
- 51) Becske T, Kallmes DF, Saatci I, McDougall CG, Szikora I, Lanzino G, et al. Pipeline for uncoilable or failed aneurysms: results from a multicenter clinical trial. *Radiology*. 2013;267(3):858-68.
- 52) Kulcsar Z, Wetzel SG, Augsburg L, Gruber A, Wanke I, Rufenacht DA. Effect of flow diversion treatment on very small ruptured aneurysms. *Neurosurgery*. 2010;67(3):789-93.
- 53) Cebal JR, Mut F, Raschi M, Scrivano E, Ceratto R, Lylyk P, et al. Aneurysm rupture following treatment with flow-diverting stents: computational hemodynamics analysis of treatment. *AJNR* 2011;32(1):27-33.
- 54) Berge J, Tourdias T, Moreau JF, Barreau X, Dousset V. Perianeurysmal brain inflammation after flow-diversion treatment. *AJNR* 2011;32(10):1930-4.
- 55) Ding YH, Lewis DA, Kadirvel R, Dai D, Kallmes DF. The Woven EndoBridge: a new aneurysm occlusion device. *AJNR* 2011;32(3):607-11.
- 56) Pierot L, Liebig T, Sychra V, Kadziolka K, Dorn F, Strasilla C, et al. Intracranial flow-disruption treatment of intracranial aneurysms: preliminary

- results of a multicenter clinical study. *AJNR* 2012;33(7):1232-8.
- 57) Lubicz B, Mine B, Collignon L, Brisbois D, Duckwiler G, Strother C. WEB device for endovascular treatment of wide-neck bifurcation aneurysms. *AJNR* 2013;34(6):1209-14.
  - 58) Cekirge HS, Saatci I, Ozturk MH, Cil B, Arat A, Mawad M, et al. Late angiographic and clinical follow-up results of 100 consecutive aneurysms treated with Onyx reconstruction: largest single-center experience. *Neuroradiology*. 2006;48(2):113-26.
  - 59) Dalyai RT, Randazzo C, Ghobrial G, Gonzalez LF, Tjoumakaris SI, Dumont AS, et al. Redefining Onyx HD 500 in the Flow Diversion Era. *International journal of vascular medicine*. 2012;2012:435-490.
  - 60) Tevah J, Senf R, Cruz J, Fava M. Endovascular treatment of complex cerebral aneurysms with onyx hd-500(R) in 38 patients. *Journal of neuroradiology Journal de neuroradiologie*. 2011;38(5):283-90.
  - 61) Struffert T, Roth C, Romeike B, Grunwald IO, Reith W. Onyx in an experimental aneurysm model: histological and angiographic results. *Journal of neurosurgery*. 2008;109(1):77-82.
  - 62) Molyneux AJ, Cekirge S, Saatci I, Gal G. Cerebral Aneurysm Multicenter European Onyx (CAMEO) trial: results of a prospective observational study in 20 European centers. *AJNR* 2004;25(1):39-51.
  - 63) Carlson AP, Alaraj A, Amin-Hanjani S, Charbel FT, Aletich VA. Continued concern about parent vessel steno-occlusive progression with Onyx HD-500 and the utility of quantitative magnetic resonance imaging in serial assessment. *Neurosurgery*. 2013;72(3):341-52; discussion 52.
  - 64) Henkes H, Fischer S, Weber W, Miloslavski E, Felber S, Brew S, et al. Endovascular coil occlusion of 1811 intracranial aneurysms: early angiographic and clinical results. *Neurosurgery*. 2004;54(2):268-80; discussion 80-5.
  - 65) Cloft HJ, Kallmes DF. Cerebral aneurysm perforations complicating therapy with Guglielmi detachable coils: a meta-analysis. *AJNR* 2002;23(10):1706-9.
  - 66) Brinjikji W, Lanzino G, Cloft HJ, Rabinstein A, Kallmes DF. Endovascular treatment of very small (3 mm or smaller) intracranial aneurysms: report of a consecutive series and a meta-analysis. *Stroke; a journal of cerebral circulation*. 2010;41(1):116-21.
  - 67) Grunwald IQ, Papanagiotou P, Politi M, Struffert T, Roth C, Reith W. Endovascular treatment of unruptured intracranial aneurysms: occurrence of thromboembolic events. *Neurosurgery*. 2006;58(4):612-8; discussion -8.
  - 68) Pierot L, Cognard C, Anxionnat R, Ricolfi F, Investigators C. Ruptured intracranial aneurysms: factors affecting the rate and outcome of endovascular treatment complications in a series of 782 patients (CLARITY study). *Radiology*. 2010;256(3):916-23.
  - 69) Im SH, Han MH, Kwon OK, Kwon BJ, Kim SH, Kim JE, et al. Endovascular coil embolization of 435 small asymptomatic unruptured intracranial aneurysms: procedural morbidity and patient outcome. *AJNR* 2009;30(1):79-84.
  - 70) Kim BM, Park SI, Kim DJ, Kim DI, Suh SH, Kwon TH, et al. Endovascular coil embolization of aneurysms with a branch incorporated into the sac. *AJNR* 2010;31(1):145-51.
  - 71) Dinc H, Kuzeyleli K, Kosucu P, Sari A, Cekirge S. Retrieval of prolapsed coils during endovascular treatment of cerebral aneurysms. *Neuroradiology*. 2006;48(4):269-72.
  - 72) Park HK, Horowitz M, Jungreis C, Genevro J, Koebbe C, Levy E, et al. Periprocedural morbidity and mortality associated with endovascular treatment of intracranial aneurysms. *AJNR* 2005;26(3):506-14.
  - 73) Paramasivam S, Leesch W, Fifi J, Ortiz R, Niimi Y, Berenstein A. Iatrogenic dissection during neurointerventional procedures: a retrospective analysis. *Journal of neurointerventional surgery*. 2012;4(5):331-5.